

# Case Report

## Sturge-Weber syndrome. A case report

Humayun Iqbal Khan, Mhammad Faheem Afzal, Fariha Anjum, Tahir Javed

Department of Pediatrics, King Edward Medical University, Lahore

**Abstract** Sturge-Weber syndrome is a rare disorder that occurs sporadically with a frequency of 1:50,000. It is characterized by facial nevus, seizures, hemiparesis, intracranial calcification and mental retardation. We report here a case of Sturge-Weber syndrome who presented with features suggestive of this syndrome having facial nevus extending to other half of the face, as well. Supportive treatment was offered.

**Key words**

Sturge-Weber syndrome.

### Introduction

Sturge-Weber syndrome is a rare disorder that occurs with a frequency of 1: 50,000.<sup>1</sup> It is a sporadic neurocutaneous disease characterized by facial port-wine stain, ocular abnormalities (glaucoma and choroidal hemangioma) and leptomeningeal angioma most often involving occipital and posterior parietal lobes.<sup>2</sup> This syndrome consists of constellation of symptoms and signs including a facial nevus, seizures, hemiparesis, intracranial calcification and mental retardation.<sup>3</sup>

Encephalofacial angiomatosis<sup>4</sup> or encephalotrigeminal angiomatosis are used as synonyms of the syndrome as angiomas involve the leptomeninges and skin of the face typically in the ophthalmic and maxillary distributions of the trigeminal nerve. Developmental disorders are more common when angiomas are bilateral.<sup>5</sup>

### Case report

A three and a half year old boy was brought to Pediatric emergency who presented with right sided tonic clonic seizures with facial twitching lasting for 45 minutes associated with frothing from mouth, loss of consciousness and right sided hemiparesis. Episode of seizures was not associated with urinary or fecal incontinence. He had similar episodes of seizures one year ago which was relieved spontaneously without any residual damage. He was born full term following uneventful birth events. He was a product of non-consanguineous marriage and was amongst the family of three siblings who were perfectly well. He was developmentally normal child with delayed speech. He was vaccinated and belonged to poor socioeconomic group.

Physical examination revealed an afebrile toddler with pulse rate of 120 per minute, respiratory rate of 34 per minute and his blood pressure was 90/70mmHg. There was port-wine stain involving upper left half of face and eyelids extending to the right half of face, as well (**Figure 1**). He was drowsy but arousable with Glasgow-coma scale of

---

**Address for correspondence**

Dr. Humayun Iqbal Khan,  
Assistant Professor,  
Department of Pediatrics,  
King Edward Medical University, Lahore  
Email: hik70@hotmail.com

13/15, upper motor type of right facial nerve palsy with right sided hemiparesis. Rest of neurological and physical examination was unremarkable. Ophthalmologic examination performed under general anesthesia revealed no abnormality.

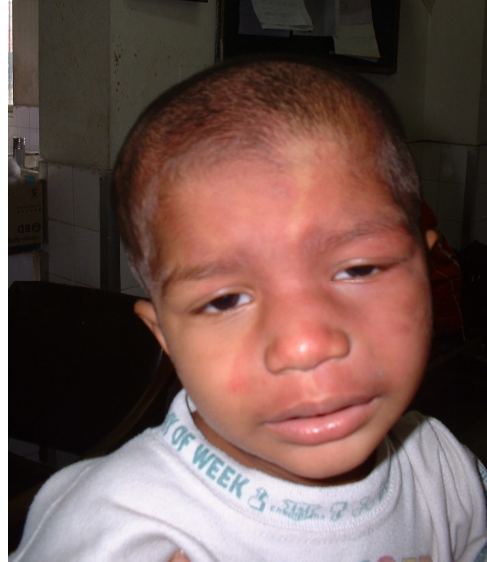Hematological and biochemical profile was within normal range. Skull radiograph was normal. CT scan brain showed atrophic right frontal lobe with large area of intracranial calcification in right frontal and left parietal region (**Figure 2**).

Immediately after transfer to our emergency unit, peripheral venous access was established. Appropriate anticonvulsants, antibiotics and fluids were administered. His progress was satisfactory. Seizures were controlled and his residual neurological deficit resolved within 6 hours. He was conscious and started taking orally. On 4<sup>th</sup> day of admission, child was discharged on anticonvulsant therapy and was kept on our regular follow-up.

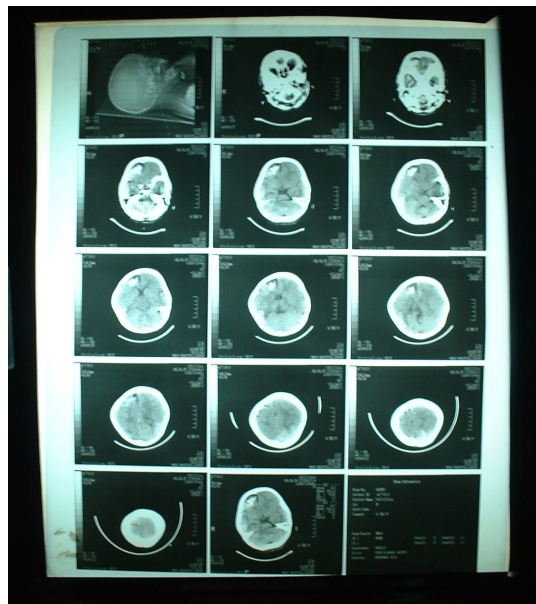
Features suggestive of Sturge-Weber syndrome in this child were facial port-wine stain, focal seizures opposite to the side of nevus, hemiparesis and intracranial calcification.

### Discussion

Sturge-Weber syndrome is a rare neurocutaneous disorder and is referred to as complete when both central nervous system and facial angiomas are present and incomplete when only one area is affected without the other.<sup>5</sup> Our patient had complete Sturge-Weber syndrome.



**Figure 1** Facial nevus extending to the opposite half of the face.



**Figure 2** CT scan of brain showing atrophic right frontal lobe with large area of intracranial calcification in right frontal and left parietal region.

The inheritance of Sturge-Weber syndrome is sporadic<sup>4</sup> and it occurs with a frequency of 1: 50,000.<sup>1</sup> Both the sexes are equally affected and no racial difference has been reported.<sup>5</sup> Although the precise pathogenesis is unknown, it is thought to be the result of anomalous development of the primordial

vascular bed during early stages of cerebral vascularization.<sup>3</sup>

Sturge-Weber syndrome has been reported in neonates, as well.<sup>6</sup> A case of 2 days old baby has been reported who presented to an emergency department after an acute life threatening event.<sup>7</sup> A case of a 14 years old girl and a 45 years old man has also been described.<sup>8,9</sup> Cases have also been reported with the sole presentation of headache.<sup>10</sup> However, a few cases without facial nevus have been reported as well.<sup>4</sup> Our patient had facial nevus extending to the other half of face as well (**Figure 1**).

Skull radiograph, CT and MRI scans show diagnostic intracranial calcification.<sup>3</sup> Indocyanine green angiography can provide information that is not detected by clinical or fluorescence angiographic examination in patients with Sturge-Weber syndrome. CT scan brain of our patient showed atrophic right frontal lobe with large area of intracranial calcification in right frontal and left parietal region (**Figure 2**). We could not have Indocyanine green angiography due to lack of diagnostic facilities. This may be important and sensitive in detecting the diffuse choroidal hemangioma associated with Sturge-Weber syndrome.<sup>11</sup> Treatment involves early control of seizures and prevention of complications.<sup>4</sup>

The parents of all the diagnosed patients must receive counseling concerning the potential risk of affected offspring. Parents should be educated about the potential complications of the disease as well.

## References

1. Thomas-Sohl KA, Vaslow DF, Maria BL. Sturge-Weber syndrome: a review. *Pediatr Neurol* 2004; **30**: 303-10.
2. Baselga E. Sturge-Weber syndrome. *Semin Cutan Med Surg* 2004; **23**:87-98.
3. Haslam R. Neurocutaneous syndromes. In: Behrman RE, Kliegman RM, Jenson HB, editors. *Nelson Textbook of Pediatrics, 17<sup>th</sup> edn*. Philadelphia: WB Saunders; 2004. p. 2015-9.
4. Moe P, Seay AR. Neurologic and muscular disorders. In: Hay WW, Hayward AR, Levin MJ, Sondheimer JM, editors. *Current Pediatric Diagnosis and Treatment, 16<sup>th</sup> edn*. Singapore: McGraw Hill; 2003. p. 717-92.
5. Riviello JR, Baumann R, Talavera F, Mack KJ, Benbadis SR, Lorenzo N. Sturge-Weber syndrome. [online] 2005 [cited 2005 Sep 27]. Available from:URL:<http://www.emedicine.com/n euro/topic356.htm>.
6. Zhuo BY, Lu GJ, Ye ZZ, Han Y. A case of Sturge-Weber syndrome. *Zhonghua Er Ke Zq Zhi* 2004; **42**: 944.
7. Muniz AE. Sturge-Weber syndrome presenting as an acute life threatening event. *Pediatr Emerg Care* 2004; **20**: 610-2.
8. Dorothy A, Kamboj M, Reddy BS, Mahajan S, Boaz K. Sturge-Weber syndrome. *Indian J Dent Res*.2004 Oct-Dec; **15**(4):152-4.
9. Hussain MS, Emery DJ, Lewis JR, Johnston WS. Sturge-Weber syndrome diagnosed in a 45 year old man. *CMAJ* 2004; **170**:1672.
10. Lisotto C, Mainardi F, Maggioni F, Zanchin G. headache in Sturge-Weber syndrome: a case report and review of the literature. *Cephalalgia* 2004; **24**: 1001-4.
11. Chen C, Yu Y, Zhen H. Sturge-Weber syndrome associated with early diffuse choroidal hemangioma: a case report. *Yan Ke Xue Bao* 2004; **20**: 168-70.