

Effectiveness and safety of minocycline 4% cream vs. clindamycin 1% cream in the treatment of mild to moderate acne vulgaris: A non-randomized clinical trial

Mahnoor Tahir, Mahnoor Shaukat Salim, Sumera Hanif, Rabya Shokat, Aliza Hamadani, Ayesha Arshad Chattha, Iram Kausar, Kiran Javaid, Haroon Nabi

Department of Dermatology, Ghurki Trust Teaching Hospital /Lahore University of Biological & Applied Sciences (UBAS), Lahore.

Abstract

Background Acne vulgaris is a polyetiological disease, associated with significant physical and psychosocial morbidity. Despite the proven efficacy, long-term use of oral minocycline is limited by its potential systemic side effects. Recent developments reveal topical minocycline 4% formulations have been found to be effective in mild to moderate acne vulgaris with minimum side effects.

Objective To compare the effectiveness and safety of minocycline 4% cream with clindamycin 1% cream in the treatment of mild to moderate acne vulgaris.

Methods In this non-randomized, prospective case-control clinical trial conducted at the Dermatology OPD, Ghurki Trust Teaching Hospital, Lahore, a total of 62 patients aged 12-45 years with mild to moderate acne were enrolled and divided into two groups. Group A (n=31) was treated with clindamycin 1% cream and group B (n=31) with minocycline 4% cream for 12 weeks. The effectiveness was determined using the Global Acne Assessment Score (GAAS) and the Investigator's Global Assessment (IGA) at baseline and week 12. Safety was determined by monitoring any local side effect. Relapses were assessed after 24 weeks.

Results Both topical treatments were effective in terms of improvement GAAS/IGA scores ($P<.001$). However, a total lesion count (TLC) reduction of almost 88.5% has achieved for minocycline and 65.8% for clindamycin ($P=.015$). Therapeutic effects of minocycline were seen earlier. In group A, 6.5% of patients had erythema and 6.5% had burning whereas in group B, only 3.2% had burning. Both drug groups were generally well tolerated.

Conclusion Minocycline 4% cream may be an effective and alternative for the treatment of mild to moderate acne vulgaris.

Keywords Minocycline; Acne vulgaris; Clindamycin.

Article
Received on
23.01.2026

Revised on
29.03.2026
09.06.2026

Accepted on
10.06.2026

Published on
30.06.2026

Citation: Tahir M, Salim MS, Hanif S, Shokat R, Hamadani A, Chattha AA, Kausar I, Javaid K, Nabi H. Effectiveness and safety of minocycline 4% cream vs. clindamycin 1% cream in the treatment of mild to moderate acne vulgaris: A prospective non-randomized comparative clinical trial. *J Pak Assoc Dermatol.* 2026;36(2):202-208. **Doi:** <https://doi.org/10.66344/jpad.v36i2.3324>

Introduction

Acne vulgaris, a recurrent inflammatory disorder of pilosebaceous units which predominantly affects

adolescents and young adults and can persist longer in adulthood. Common presenting features are comedones, papules, pustules, nodular lesions and scarring.¹ This condition can significantly impact the mental health and psychosocial development of affected individuals.

Address for correspondence

Dr. Mahnoor Tahir, PGR
Department of Dermatology,
Ghurki Trust Teaching Hospital, Lahore, Pakistan.
Email: mahnoortahir788@gmail.com

The disease shares multiple pathogenic phenomena

including sebaceous gland hyperactivity, hyperkeratinisation of gland ducts and overgrowth of *Cutibacterium acnes* leading to the activation of inflammatory cascade.^{2,3} The aim of long term management is a balance between the clinical effectiveness, safety profile of drug and adherence towards treatment protocol.^{4,5} Topical therapy remains the mainstay in the treatment of acne. Among commonly used topical agents are retinoids, benzoyl peroxide, and antibiotics like clindamycin.⁶⁻⁸ In severe cases, systemic therapy with antibiotics mostly doxycycline and minocycline, isotretinoin and antiandrogens is warranted.^{8,9} Minocycline is one of the most commonly used therapy, it has its own side effects including hepatotoxicity, rare immune-mediated reactions, vestibular disturbance and raising concerns of antimicrobial resistance.¹⁰ Amongst topical antibiotics clindamycin has been frequently used in the treatment of mild to moderate acne; nonetheless, reduced efficacy of clindamycin has been reported due to increasing bacterial resistance. Recently topical minocycline has been approved by the FDA as a topical treatment in acne vulgaris while minimizing its systemic toxicity.^{10,11} Various formulations including foams, gels, and creams of minocycline have been found to be effective.^{8,10,11} Both topical minocycline and clindamycin have bacteriostatic and anti-inflammatory properties against *Cutibacterium acnes*.^{12,13} Topical delivery allows targeted drug absorption.¹⁴ This targeted therapy works efficiently in controlling inflammation and bacterial growth.^{15,16} Nevertheless direct comparative data regarding effectiveness and safety of on topical minocycline and topical clindamycin is scanty especially in local population.¹⁷⁻²² The current study was pursued to compare the effectiveness and safety profile of topical minocycline 4% cream and topical clindamycin 1% cream among patients with acne vulgaris.²³

Methods

This study was designed as a prospective non-randomized, case-control clinical trial conducted in

a resource limited setting, carried out over a one-year period in the Outpatient Department of Dermatology, Gurki Trust Teaching Hospital, Lahore. Ethical approval of the study was taken from the institutional review board (Ref. No. 2025/02/R-03 dated 01.02.2025).

The sample size of 62 patients (31 in each group A and B) was determined using a confidence interval of 90% and power 85%. After informed consent, 62 patients (12-45years) suffering from mild to moderate acne vulgaris were enrolled by using non-probability consecutive sampling technique. Treatment allocation was based on the clinical judgement and patient's preference. Inclusion criteria of the study comprised clinically labelled cases 18-45 years of age falling in mild to moderate category of acne vulgaris on face based on Global Acne Assessment Score (GAAS).¹ Exclusion criteria-heightened sensitivity to any of the drug i.e. clindamycin or minocycline, use of any treatment in preceding weeks (4 weeks for systemic and 2 weeks for topical), pregnancy or lactation, and/or presence of nodulocystic acne. The initial assessment included history, clinical examination, and standard investigations, such as complete blood count (CBC), liver function tests (LFTs), and renal function tests (RFTs). The severity of acne was assessed at baseline and subsequent visits by counting both inflammatory and non-inflammatory lesions manually and using GAAS and Investigators Global Assessment (IGA) score. A photographic evaluation of the lesion was carried out. GAAS scores were 0 (no acne), 1 (minimal acne), 2 (mild acne), 3 (moderate acne) and 4 (severe acne), while IGA scores were 0= clear, 1= almost clear, 2= mild acne, 3= moderate acne, and 4= severe acne.⁶ Standardized clinical photographs were obtained at each visit.¹

Of 62 patients, 31 patients allocated to group A (Clindamycin group) and 31 to group B (minocycline group). Group A was treated with topical clindamycin 1% cream, while Group B with topical minocycline 4% cream. Patients were advised to apply the prescribed cream after washing

face twice daily for total duration of 12 weeks. The effectiveness of the treatment was evaluated at 2, 4, 6, 8, and 12 weeks. Each participant was called for a follow up at 24 weeks to document relapses if any. The primary outcomes were defined as the treatment success if GAAS and/ or IGA scores were 0 or 1. Adverse events like itching, burning, erythema, edema, scaling, dryness etc. were recorded throughout the study duration.

Data were collected through patient’s proforma and images taken with mobile camera of 108 MP; subsets were analysed through IBM SPSS 27. Qualitative variables including gender, response to treatment, and side effects were calculated as frequencies and percentages. For quantitative factors (age, length of illness, GAAS Score for inflammatory, noninflammatory, and total lesions), mean and standard deviation were computed. Age, gender, and length of illness were utilized to stratify the data, and the IGA score at baseline and the major end point was determined using a post-stratification paired t-test. The effectiveness was assessed using the chi square test and a *P*-value. The change in the number of lesions from baseline to different time points were compared within each arm and between two arms using Mann–Whitney U test. Wilcoxon signed-rank test was used to compare the median between the two groups. *P*-value $\leq .05$ was defined as statistically significant. Normality of continuous variable was assessed using the Shapiro Wilk test. As most variables were not normally distributed ($P < .05$), data are presented as median (IQR) and

non-parametric tests were used for analysis.

Result

Table 1 shows the preclinical parameters in the two treatment groups. Both groups were comparable in terms of demographic characteristics. Female gender was predominant in both groups, with most of patients falling under the age of 30. Median for duration of disease was comparable between both study groups with group A highlighting a long duration of 9 months as compared to group B showing 6 months duration.

Clinical improvement is shown in **Figures 1-4** and **Table 2**. As evident in **Figure 2**, a significant

Table 1 Demographic profile and disease duration among study participants (n=62).

Outcome	Group A (n=31) (Clindamycin) Frequency (%)	Group B (n=31) (minocycline) Frequency (%)
Gender		
Male	6 (19.4%)	5 (16.1%)
Female	25 (80.6%)	26 (83.9%)
Age (years)	22 (20-25%)	24 (20-27%)
Age Group		
<30 years	28 (90.3%)	29 (93.5%)
≥30 years	3 (9.7%)	2 (6.5%)
Disease duration (months)	9 (6-13)	6 (5-10)
Duration group		
3-6 months	9 (29%)	18 (58.1%)
7-12 months	14 (45.2%)	13 (41.9%)
>12 months	8 (25.8%)	0 (0)
Marital Status		
Married	7 (22.6%)	10 (32.3%)
Un-Married	24 (77.4%)	21 (67.7%)
Median (1 st quartile-3 rd Quartile)		

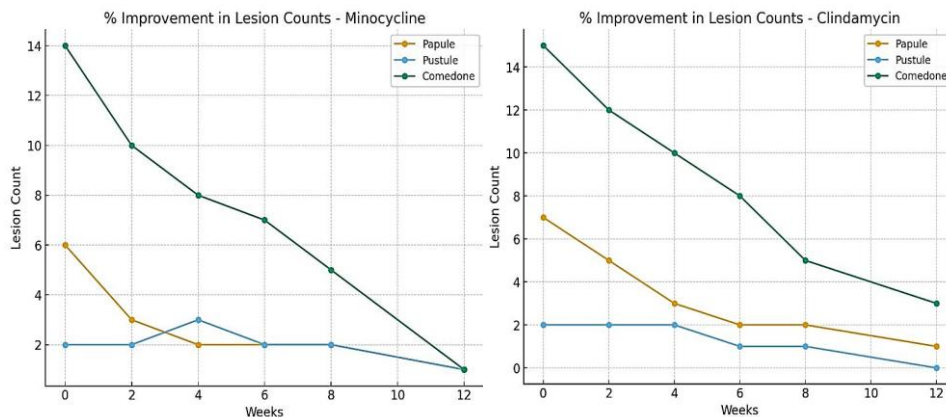


Figure 1 Total lesion count over the time in two treatment groups.

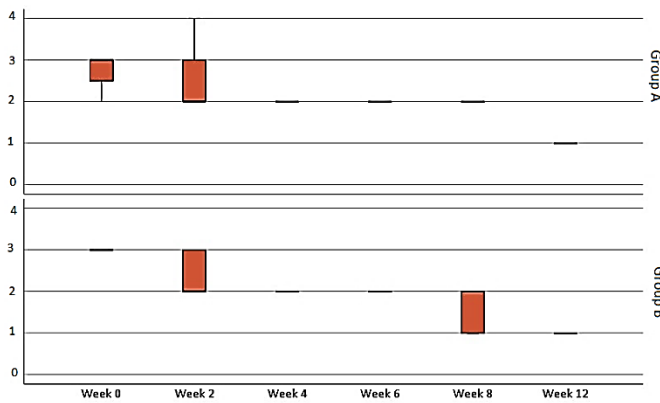


Figure 2 Global Acne Assessment Score (GAAS) overtime

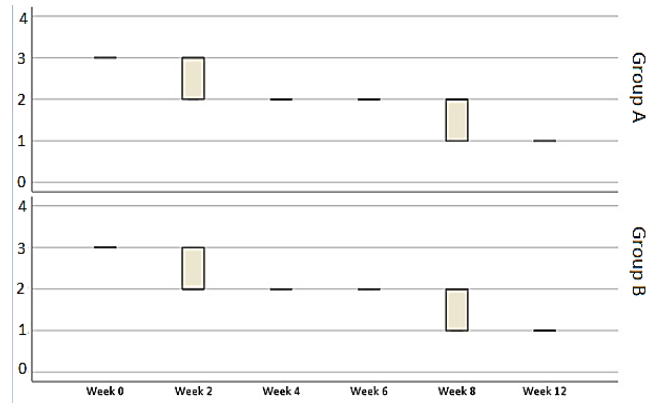


Figure 3 Investigators global assessment score (IGA Score) over time

Table 2 Comparison of clinical scores

	Median (Q1-Q3)		P-value \uparrow	Comparison with Week 0	p-value [
	Group A	Group B			Group A	Group B
Global Acne Assessment Score (GAAS)						
Week 0	3 (2-3)	3 (3-3)	.101			
Week 2	2 (2-3)	2 (2-3)	.890	Week 2 versus Week 0	<.001*	<.001*
Week 4	2 (2-2)	2 (2-2)	.154	Week 4 versus Week 0	<.001*	<.001*
Week 6	2 (2-2)	2 (2-2)	.078	Week 6 versus Week 0	<.001*	<.001*
Week 8	2 (2-2)	2 (1-2)	.158	Week 8 versus Week 0	<.001*	<.001*
Week 12	1 (1-1)	1 (1-1)	.628	Week 12 versus Week 0	<.001*	<.001*
P-value \leftrightarrow	<.001*	<.001*	-			
Investigators Global Assessment Score (IGA Score)						
Week 0	3 (3-3)	3 (3-3)	.759			
Week 2	3 (2-3)	2 (2-3)	.801	Week 2 versus Week 0	<.001	<.001*
Week 4	2 (2-2)	2 (2-2)	.557	Week 4 versus Week 0	<.001	<.001*
Week 6	2 (2-2)	2 (2-2)	1.000	Week 6 versus Week 0	<.001	<.001*
Week 8	2 (1-2)	2 (1-2)	.801	Week 8 versus Week 0	<.001	<.001*
Week 12	1 (1-1)	1 (1-1)	.672	Week 12 versus Week 0	<.001	<.001*
P-value \leftrightarrow	<.001*	<.001*	-			

\uparrow Mann Whitney U test was applied. \leftrightarrow Friedman test was applied. [Wilcoxon signed rank test was applied. P-value \leq .05 considered as significant. *Significant at .05 levels.

reduction in the mean number of papules, pustules and comedones was seen in each treatment group A and B ($P<.05$); however, inflammatory lesions (papules and pustules) showed an earlier improvement than non-inflammatory (comedones) in both groups.

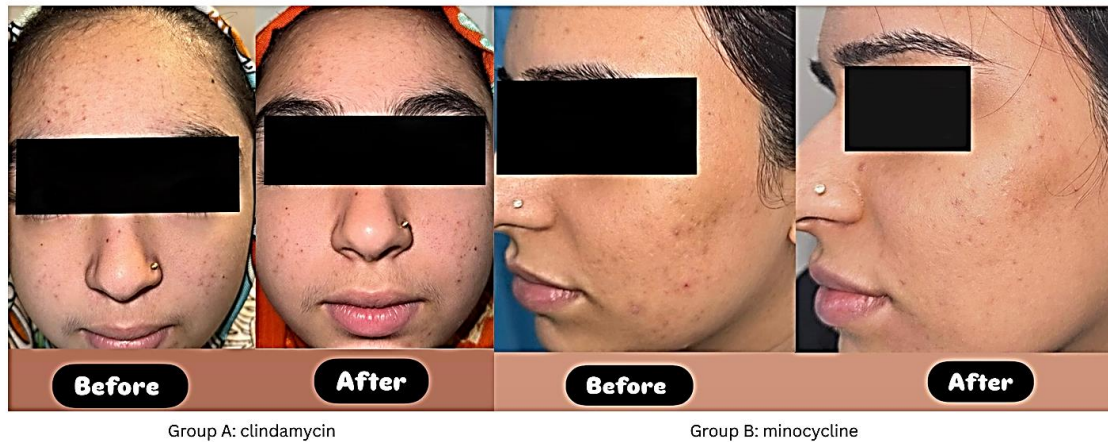Table 2 and **Figures 2-3** show the median GAAS and IGA score and baseline and at follow-up visits. The median score in individual groups reduced from 3 at baseline to 1 at week 12 ($P<.001$). Nonetheless, the difference between group A and B was insignificant, i.e. both treatment groups were equally effective. A 33% improvement was evident by the week of treatment in both groups: however, the

further 67% improvement in subsequent 8 weeks.

Regarding the safety of two treatments, no side effects were seen in both groups i.e. both treatments were safe.

Discussion

Our study demonstrated comparable clinical benefits of minocycline cream with clindamycin cream. The cream formulation was used to provide uniform drug delivery and minimize the systemic absorption. Total lesion counts showed improvements in the minocycline group by week 12 as good as clindamycin. Minimal adverse effects;



Group A: clindamycin

Group B: minocycline

Figure 4 Comparison of both drug groups pre and post treatment

3.2% of the patients had burning only, suggesting its good tolerability. Presenting topical minocycline as an effective alternative for topical therapies in acne that fall in the category of mild to moderate.

Our study results coincide with the previous trials on topical formulation of minocycline in acne vulgaris. Phase II and III clinical trials that tested minocycline formulation in foam (FMX101 4%) on patients with acne vulgaris in comparison with vehicle controls showed a promising decrease of inflammatory lesion counts at week 12, with an impacting effect on Investigator's Global Assessment. However, differences in formulations of both minocycline and clindamycin 4%-1% may influence drug penetration affecting the treatment outcomes. In addition, the variation between cream and foam can further impact the drug delivery.^{8,10} Importantly, review studies concluded that use of minocycline can be prolonged without significant systemic toxicity.⁶ A recent phase III trial conducted in China, showed consistent results with our study.¹²

Considering all these trials and our study results the findings substantiate the concept that topical minocycline is an effective and safe treatment in acne vulgaris.¹⁵

Increasing resistance of *Cutibacterium acnes* towards antimicrobial therapies worldwide emphasizes the need of alternative treatment regimes. The dual mechanism of action of

minocycline with both anti-bacterial and anti-inflammatory properties, makes it an overall superior regimen. There is evidence of its utilization in other inflammatory dermatoses further supporting its therapeutic superiority. A phase IIb clinical trial evaluated topical minocycline gel in papulopustular rosacea with positive results and overall high global assessment response rate in the active treatment group. All these findings suggest minocycline has a broader spectrum of action in dermatological diseases, but the observed results cannot be attributed solely to the pharmacological properties of the drug due to the difference in formulations and vehicle.¹⁷

Safety profile of minocycline is relatively good and consistent with the previous study.¹³ Systemic side effects of oral minocycline include drug-induced lupus, hypersensitivity reactions, and intracranial hypertension. Topical therapy negates all these systemic side effects and delivers localized drug to the targeted area respectively.^{13,15} This targeted therapeutic role of minocycline makes it an attractive safe option for prolonged use.^{10,11}

There were certain limitations in our study that should be acknowledged, the non-randomization, as the allocation was done on clinical feasibility and preference of patients which may have led to selection bias and small sample sizes due to strict inclusion criteria and limited duration of study within a single centre restricted our study findings.

The short duration of study constrains us from finding out the long-term effectiveness and delayed side effects of the drug. There is further need of randomized, multicentric studies with long duration of follow-up to compare topical minocycline with first line therapies for a definite conclusion of its therapeutic superiority.¹³

Conclusion

Our study infers that topical minocycline 4% cream is as effective and safe as clindamycin 1% cream in mild to moderate acne vulgaris. Nevertheless, large scale studies of prolonged durations are needed for more sustained results and assessment of relapse.

Declaration of patient consent Authors certify that they have obtained all appropriate patients' consent.

Financial support and sponsorship None.

Conflict of interest No conflict of interest.

Author's contribution

MT,MSS: Substantial contributions to study design, acquisition of data and manuscript writing.

SH,RS,AH,AAC,IK,HN: Substantial contributions to study design, acquisition of data and critical review of the manuscript.

Every author has given final approval of the manuscript version to be published and agreed to be accountable for all aspects of the work.

References

1. Shah B, Mistry D, Gonsalves N, Vasani P, Dhoot D, Barkate H. A Prospective, Randomized, Comparative Study of Topical Minocycline Gel 4% with Topical Clindamycin Phosphate Gel 1% in Indian Patients with Acne Vulgaris. *Antibiotics (Basel)*. 2023 Sep 19;**12(9)**:1455. doi: 10.3390/antibiotics12091455.
2. Kircik LH, Stein Gold L, Gold M, Weiss JS, Harper JC, Del Rosso JQ, *et al*. Triple Combination Clindamycin Phosphate 1.2% /Adapalene 0.15%/Benzoyl Peroxide 3.1% for Acne: Efficacy and Safety from a Pooled Phase 3 Analysis. *Dermatol Ther (Heidelb)*. 2024;**14(5)**:1211-27.
3. Shaheen EA, Aljefri YE, Ghaddaf AA, Alshareef KM, Alhindi AK, Alanazi NF, *et al*. The efficacy and safety of minocycline, metronidazole, ivermectin, and azelaic acid in moderate-to-severe papulopustular rosacea: A systematic review and network meta-analysis. *J Am Acad Dermatol Int*. 2025;**20**:23-30.
4. Dhoot D, Budamakuntla L, Parasramani S, Deshmukh G, Barkate H. Acne in Indian population: An epidemiological study evaluating multiple factors. *IP Indian J Clin Exp Dermatol*. 2020;**6(3)**:237-42.
5. Heng AHS, Chew FT. Systematic review of the epidemiology of acne vulgaris. *Sci Rep*. 2020;**10(1)**:5754.
6. Stein Gold L, Dhawan S, Weiss J, Draelos ZD, Ellman H, Stuart I. Open-label Extension Study Evaluating Long-term Safety and Efficacy of FMX101 4% Minocycline Foam for Moderate-to-Severe Acne Vulgaris. *J Clin Aesthet Dermatol*. 2019;**12(10)**:16-23.
7. Reynolds RV, Yeung H, Cheng CE, Cook-Bolden F, Desai SR, Druby KM, *et al*. Guidelines of care for the management of acne vulgaris. *J Am Acad Dermatol*. 2024;**90(5)**:1006 e1-e30.
8. Xu JH, Lu QJ, Huang JH, Hao F, Sun QN, Fang H, Gu J, Dong XQ, Zheng J, Luo D, Li FQ. A multicentre, randomized, single-blind comparison of topical clindamycin 1% benzoyl peroxide 5% once-daily gel versus clindamycin 1% twice-daily gel in the treatment of mild to moderate acne vulgaris in Chinese patients. *J Eur Acad Dermatol Venereol*. 2016 Jul;**30(7)**:1176-82.
9. Shemer A, Shiri J, Mashiah J, Farhi R, Gupta AK. Topical minocycline foam for moderate to severe acne vulgaris: Phase 2 randomized double-blind, vehicle-controlled study results. *J Am Acad Dermatol*. 2016;**74(6)**:1251-2.
10. Zaenglein AL, Pathy AL, Schlosser BJ, Alikhan A, Baldwin HE, Berson DS, *et al*. Guidelines of care for the management of acne vulgaris. *J Am Acad Dermatol*. 2016;**74(5)**:94573 e33.
11. Gupta AK, Bruce A, Vincent KD, Abramovits W. Amzeeq (minocycline foam 4%) for topical treatment of acne vulgaris. *Skinmed*. 2020 Dec 1;**18(6)**:354-7. PMID: 33397564.
12. Kircik L, Del Rosso JQ, Weiss JS, Stakias V, London A, Keynan R, Hazot Y, Elliott R, Stuart I. Formulation and Profile of FMX101 4% Minocycline Topical Foam for the Treatment of Acne Vulgaris. *J Clin Aesthet Dermatol*. 2020;**13(4)**:14-21.

13. Makrantonaki E. Topical minocycline foam: A new option for acne treatment? *J Eur Acad Dermatol Venereol*. 2025;**39(5)**:885-6.
14. Raof TJ, Hooper D, Moore A, Zaiac M, Sullivan T, Kircik L, *et al*. Efficacy and safety of a novel topical minocycline foam for the treatment of moderate to severe acne vulgaris: A phase 3 study. *J Am Acad Dermatol*. 2020;**82(4)**:832-7.
15. Altameemi FF, OSA. Topical Minocycline as treatment for Acne Vulgaris. *Medical Science*. 2021;**25(109)**:730-4.
16. Martins AM, Marto JM, Johnson JL, Graber EM. A Review of Systemic Minocycline Side Effects and Topical Minocycline as a Safer Alternative for Treating Acne and Rosacea. *Antibiotics (Basel)*. 2021;**10(7)**:757.
17. Afroz F, Hasan R, Shahriar R. A Comparative Study on Efficacy of Azithromycin and Minocycline in the Treatment of Acne Vulgaris. *J Biotech Biomedicine*. 2023;**06(02)**:265-9.
18. Webster G, Draelos ZD, Graber E, Lee MS, Dhawan S, Salman M, *et al*. A multicentre, randomized, double-masked, parallel group, vehicle-controlled phase IIb study to evaluate the safety and efficacy of 1% and 3% topical minocycline gel in patients with papulopustular rosacea. *Br J Dermatol*. 2020;**183(3)**:471-9.
19. Sumsuzzoha DSM, Sattar DMA, Das DAK, Zaman DS. A Comparative Study of Azithromycin Pulse Therapy with Minocycline in Acne Vulgaris. *Saud J Medicine*. 2022;**7(12)**:610-5.
20. Pande S, Deshmukh G, Dhoot D, Andhorikar N. An Open-label, Prospective, Comparative, Double-arm Clinical Trial to Evaluate the Safety and Effectiveness of Minocycline Extended-release Formulation Compared with Minocycline Immediate-release Formulation in the Management of Patients with Papulopustular Acne. *Indian J Drugs Dermatol*. 2020;**6(2)**:76-80.
21. Garrido-Mesa N, Zarzuelo A, Galvez J. Minocycline: far beyond an antibiotic. *Br J Pharmacol*. 2013;**169(2)**:337-52.
22. Bhavsar B, Choksi B, Sanmukhani J, Dogra A, Haq R, Mehta S, *et al*. Clindamycin 1% Nano-emulsion Gel Formulation for the Treatment of Acne Vulgaris: Results of a Randomized, Active Controlled, Multicentre, Phase IV Clinical Trial. *J Clin Diagn Res*. 2014;**8(8)**:YC05-9.
23. Basak A, Hossain MA, Sharmin S, Sarker S. A Comparative Study on Efficacy of Oral Azithromycin and Oral Minocycline for the Treatment of Acne Vulgaris. *Mugda Med Coll J*. 2025;**8(1)**:13-6.
24. Pradhan M, Prajapati S, Bichchha R, Guragain A. Comparative study on efficacy of benzoyl peroxide with adapalene versus plain adapalene in the treatment of acne vulgaris. *Nep Mediciti Med J*. 2024 Aug;**5(1)**:25-33.