

Lactic acid peeling in the treatment of epidermal melasma

Saadiya Siddiqui, Tariq Rashid

Department of Dermatology, Sir Ganga Ram Hospital, Lahore

Abstract *Objective* To determine the efficacy of lactic acid peeling in the treatment of melasma.

Methods This quasi- experimental study was carried out at department of Dermatology, Sir Ganga Ram Hospital, Lahore. A total number of 40 patients, with age ranging from 20-50 years were included in the study. All patients were female except 2. All patients underwent lactic acid peeling sessions at 3 weekly intervals for a total 6 sessions. The severity of melasma was assessed by MASI score. Efficacy was based on mean decrease in MASI score at baseline and MASI score three weeks after the completion of treatment.

Results Mean of MASI scores of all these subjects at baseline was 12.62, and the mean MASI score recorded at the final follow-up was 6.30. Mean decrease in MASI scores was 6.32.

Conclusion Lactic acid peeling is effective in the treatment of epidermal type of facial melasma in Asian skin.

Key words

Lactic acid peeling, melasma, efficacy.

Introduction

Melasma is a commonly acquired, localized usually symmetric hyperpigmentation characterized by irregular, light to dark brown patches that occur almost exclusively in sun exposed areas.¹ This condition is most common in women accounting for 90% of all cases especially in pregnant women,² those on hormone replacement therapy or oral contraceptive medications.³ It appears in all racial types but occurs more frequently in those persons with Fitzpatrick skin type IV – VI who live in areas of high ultraviolet radiations; sun exposure deepens these hyper pigmented areas.^{3,4,5,6} There are three types of melasma,

differentiated on the basis of Wood's lamp examination; epidermal, dermal and dermoepidermal.⁵

Treatment of melasma involves the use of topical hypopigmenting agents, such as hydroquinone,⁷ tretinoin, kojic acid, azelaic acid,⁸ quasi drugs,⁹⁻¹⁴ L-ascorbic acid,¹⁵ physical therapies such as chemical peels (glycolic acid, trichloroacetic acid), laser therapy¹⁶⁻²² and dermabrasion, similar to that used in other hyperpigmentary disorders, have also been evaluated with varying degrees of success.^{4,24}

Lactic acid is a member of α -hydroxy acids family. Alpha hydroxy acids such as lactic acid improves melasma by inhibiting tyrosinase enzyme directly therefore suppressing melanin formation.²⁵ It also increases keratinocyte turnover and decrease corneocyte cohesion

Address for correspondence

Dr. Saadiya Siddiqui,
Department of Dermatology,
Sir Ganga Ram Hospital, Lahore
Email: saadiyas7@gmail.com

thereby decreasing stratum corneum thickness which hastens the resolution of melasma.²⁵

This study was undertaken to determine the efficacy of lactic acid peeling in melasma.

Methods

This quasi-experimental study was carried out at department of Dermatology, Sir Ganga Ram Hospital, Lahore. Sample size of 40 cases was calculated with 95% confidence level, $d=1$ and taking mean \pm SD of mean decrease in MASI score i.e. 7.97 ± 3.168 after lactic acid peeling for the treatment of melasma. Non-probability purposive sampling technique was used in this study. Inclusion criteria for study were epidermal type of melasma of any severity and any duration assessed on Wood's lamp examination, patients of both genders with age ranging from 20-60 years and face involvement only.

Patients taking other treatment for melasma in last one month, pregnant and lactating women, those using contraceptive pills, having known hypersensitivity to alpha hydroxy acids or history of photosensitizing drug intake were excluded.

After written informed consent, and an approval from ethical review board, all participants fulfilling the inclusion criteria were enrolled through outpatient department of dermatology, Sir Ganga Ram Hospital, Lahore.

Demographic data e.g. name, age, gender, address were noted each patient. Baseline melasma area severity index (MASI) scores were recorded. All recruited patients were treated by pure lactic acid (92%; pH 3.5) chemical peel. The chemical peeling sessions were done every 3 weeks for a total number of six sessions. The patients were instructed to

avoid sun exposure and apply sunblock SPF30. The severity of melasma was assessed by MASI score was recorded on predesigned proforma.

Mean was calculated for quantitative variables like age, MASI score as baseline and MASI score three weeks after the completion of treatment. Mean baseline MASI score was subtracted from final MASI score three weeks after completion of treatment and mean decrease in MASI score was calculated. Finally mean decrease of all cases was calculated at each interval of three weeks of treatment. P value ≤ 0.05 was considered as significant.

Results

A total of 40 subjects completed the study successfully, aged from 20 to 50 years with mean of 32.45 ± 7.15 years. All patients were females except two.

All patients underwent a total number of 6 peeling sessions at 3 weekly intervals and a final follow-up was done 3 weeks after the last peeling session, making a total duration of 18 weeks. Mean MASI score of all these subjects at baseline was 12.62 (**Figure 1**) and the mean MASI score recorded at the final follow-up was 6.30 (**Figure 2**). The group mean of mean decrease in MASI scores (obtained by subtracting final MASI scores from baseline MASI scores) was 6.32, among 40 study subjects (**Table 1**). Range of score also decreased as the therapy continued for all subjects (**Table 1**). Initially it was 22.5 (maximum of 28.80 and minimum of 6.30) and at the end of treatment it was 11.90 (maximum of 13.10 and minimum of 1.20) as shown in **Table 1**. Similarly improvement in MASI was also calculated for each subject separately. On analysis, range, mean and standard deviation of decrease in MASI were observed as 16.3 and 6.32 ± 4.07 , respectively (**Table 1**).

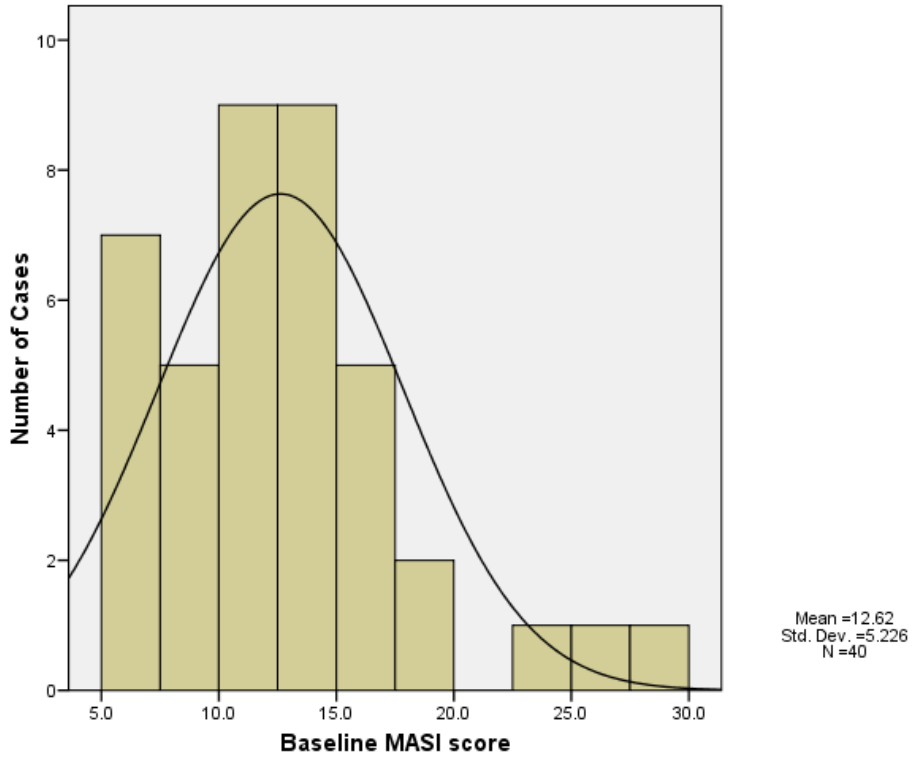


Figure 1: Histogram showing baseline score of all study subjects (N=40).

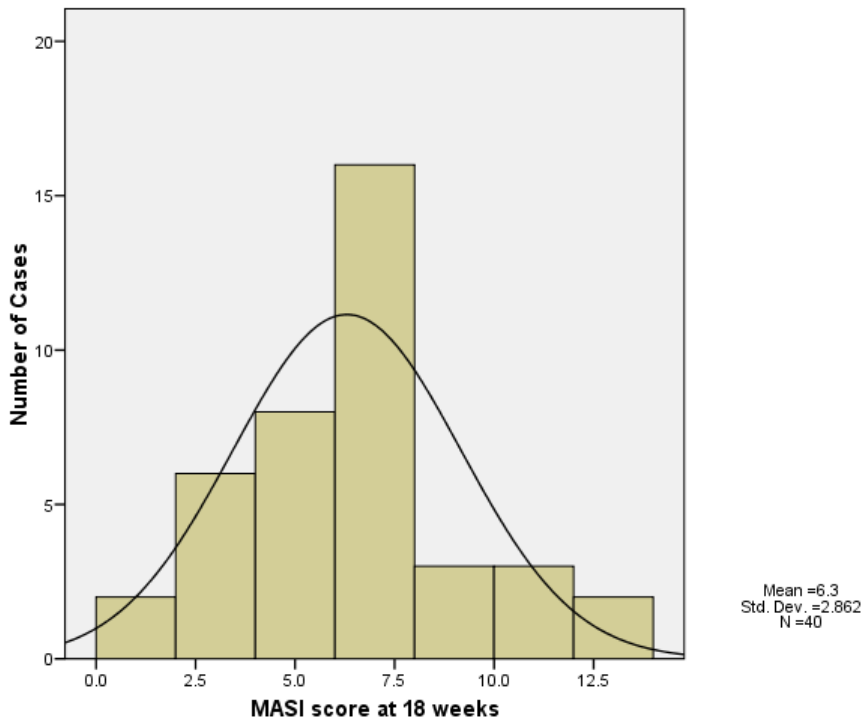


Figure 2: Histogram showing score at 18 weeks of the study subjects (N=40).

Table 1 MASI score of all study subjects on each visit (N=40).

	<i>Minimum</i>	<i>Maximum</i>	<i>Range</i>	<i>Mean</i>	<i>Standard deviation</i>
Baseline	6.30	28.80	22.50	12.62	5.23
At 3 weeks	2.60	24.40	21.80	11.26	4.55
At 6 weeks	2.00	20.80	18.80	9.98	4.40
At 9 weeks	2.00	21.20	19.20	9.31	4.17
At 12 weeks	1.20	21.60	20.40	7.78	3.44
At 15 weeks	1.20	16.80	15.60	6.75	3.19
At 18 weeks*	1.20	13.10	11.90	6.30	2.86
Group mean of mean decrease in MASI scores	0.10	16.40	16.30	6.32	4.07

* 3 weeks after end of therapy

Table 2 Decrease in MASI score of all study subjects cross-tabulated against different age groups (N=40).

	<i>Different age groups</i>			
	<i>16-25 years (N=7)</i>	<i>26-35 years (N=22)</i>	<i>36-45 years (N=10)</i>	<i>46-55 years (N=1)</i>
Decrease in MASI score (%)	17.5%	55.0%	25.0%	2.5%
Minimum	4.00	0.10	1.20	5.10
Maximum	14.80	16.40	12.10	
Mean decrease	6.63	6.81	5.15	
Standard deviation	3.74	4.59	3.27	

The decrease in mean MASI score was consistent in all age groups of the subjects; however maximum decrease was recorded in age group of 26 to 35 years of age (**Table 2**).

Discussion

Lactic acid is an alpha hydroxy acid, naturally found in yogurt, buttermilk or sour cream and some cottage cheeses. It was first isolated in 1780 by the Swedish chemist Carl Wilhelm Scheele. Lactic acid is already present in human cells, which makes it a safer peeling agent. Modern day chemical peeling was originally promoted by dermatologist P.G. Unna.²⁶

Chemical peeling is a common office procedure that has evolved over the years. In spite of the advent of newer techniques such as lasers and light therapies, peeling has stood the test of time as a simple procedure, requiring hardly any instrumentation to rejuvenate the skin.¹

MASI scores of 40 subjects at the start of treatment were slightly skewed with some

patients showing baseline high MASI scores (ranging from 6.30 to 28.80) with majority falling between MASI scores of 10 to 16. But as the treatment continued, MASI scores of all the study subjects decreased and at the end of treatment were normally distributed (**Figures 1 and 2**). At the end of our study we observed that mean MASI scores of all the study subjects at baseline decreased almost half of its initial value (**Table 1**). We observed a statistically significant decrease in MASI score (P value < 0.001).

The decrease in mean MASI score was consistent in all age groups; however maximum decrease was recorded in age group of 26-35 years with a mean decrease of 6.81. The study population belonging to this age group formed 55.0% (N=22) of the total study population (**Table 2**).

It was observed that the patients presenting with high baseline MASI scores, showed the maximum response with lactic acid peeling in terms of mean decrease in MASI scores. A maximum mean decrease recorded was 16.40 in

a patient who presented with a baseline MASI score of 28.8. This finding is in consistence with results of a similar study done previously on lactic acid peeling by Sharquie *et al.*²⁶

Another study conducted in university of Baghdad in 2006, compared lactic acid peeling to Jessner's solution peeling for treatment of melasma. Full strength lactic acid (92%) was used on the left side of face while Jessner's solution was applied on the right side of face at three weekly intervals. The mean MASI score of all the study subjects was 9.78 ± 3.16 while the MASI score after lactic acid peeling was 2.02 ± 1.53 (left side of face) and it decreased to 1.93 ± 1.48 (right side of face) after peeling with Jessner's solution.²⁷

Another study was conducted in 2004 at department of dermatology Combined Military Hospital, Malir Cantonment, Karachi.²⁸ The efficacy and safety of Jessner's solution was compared to 30% salicylic acid as superficial chemical peeling agent in the treatment of epidermal melasma in Asian skin.

Although a few international studies highlight the efficacy of lactic acid peeling in the treatment of melasma; however, in Pakistan no concrete data was available in this regard. So the results of our study have shown that lactic acid may be used in our population as a treatment modality to speed up the resolution of epidermal type of melasma in Asian skin.

Conclusion

It is concluded that lactic acid is an effective peeling agent for the treatment of epidermal type of melasma in Asian skin.

References

1. Gupta AK, Gover MD. The treatment of melasma: A review of clinical trials. *J Am Acad Dermatol.* 2006;**55**:1048-65.
2. Sarkar R, Puri P, Jain RK, Singh A, Desai A. Melasma in men: a clinical, aetiological and histological study. *J Eur Acad Dermatol Venereol.* 2010;**24**:768-72.
3. Ortonne JP, Arellano I, Berneburg M, Cestari T, Chan H, Grimes P *et al.* A global survey of the role of ultraviolet radiation and hormonal influences in the development of melasma. *J Eur Acad Dermatol Venereol.* 2009;**23**:1254-62.
4. Rendon M, Burneberg M, Arellano I, Picardo M. Treatment of melasma. *J Am Acad Dermatol.* 2006;**54**:272-81.
5. Wendy ER. Melasma. In: Kelly AP, Taylor SC, editors. *Dermatology for Skin of Color.* New York: McGraw-Hill Medical; 2009. p. 332-36.
6. Guinot C, Cheffai S, Latreille J, Dhaoui MA, Youssef S, Jaber K *et al.* Aggravating factors for melasma: a prospective study in 197 Tunisian patients. *J Eur Acad Dermatol Venereol.* 2010;**24**:1060-9.
7. Josefina NS, Juan PC, Bertha TA, Oros-Ovalle C, Fuentes-Ahumada C, González FJ *et al.* A double-blind, randomized clinical trial of niacinamide 4% versus hydroquinone 4% in the treatment of melasma. *Dermatol Res Pract.* 2011;**2011**:1-5.
8. Siddique MR, Khondker L, Hazra SC, Khan MSI. The efficacy of combination of 20 % azelaic acid with 0.05 % tretinoin cream in the treatment of melasma. *J Pak Assoc Dermatol.* 2011;**21**:265-9.
9. Hwang SW, Oh DJ, Lee D, Kim JW, Park SW. Clinical efficacy of 25% l-ascorbic acid (C'ensil) in the treatment of melasma. *J Cutan Med Surg.* 2009;**13**:74-81.
10. Rashmi S, Shikha C, Vijay KG. Newer and upcoming therapies for melasma. *Indian J Dermatol Venereol Leprol.* 2012;**78**:417-28.
11. Sailesh K, Aanand NG, Rebat MH. New horizons in treating disorders of hyperpigmentation in skin of color. *Semin Cutan Med Surg.* 2012;**31**:133-9.

12. Alvin G, Catambay N, Vergara A, Jamora MJ. A comparative study of the safety and efficacy of 75% mulberry (*Morus alba*) extract oil versus placebo as a topical treatment for melasma: A randomized, single-blind, placebo controlled trial. *J Drugs Dermatol*. 2011;10:1025-31.
13. Altaei T. The treatment of melasma by silymarin cream. *BMC Dermatol*. 2012;12:18.
14. Malek J, Chedraoui A, Nikolic D, Barouti N, Ghosn S, Abbas O. Successful treatment of hydroquinone-resistant melasma using topical methimazole. *Dermatol Ther*. 2013;26:69-72.
15. Yenny SY, Lestari W. A study comparing the use of 10% L-ascorbic acid and 10% zinc sulfate solution in the treatment of melasma. *Malay J Dermatol*. 2012;29:38-45.
16. Arielle NB, Kauvar. The evolution of melasma therapy: targeting melanosomes using low fluence Q-switched neodymium-doped yttrium aluminum garnet lasers. *Semin Cutan Med Surg*. 2012;31:126-32.
17. Kroon MW, Wind BS, Beek JF, van der Veen JP, Nieuweboer-Krobotová L, Bos JD *et al*. Nonablative 1550-nm fractional laser therapy versus triple topical therapy for the treatment of melasma: A randomized controlled pilot study. *J Am Acad Dermatol*. 2011;64:516-23.
18. Karsai S, Fischer T, Pohl L, Schmitt L, Buhck H, Jünger M *et al*. Is non-ablative 1550-nm fractional photothermolysis an effective modality to treat melasma? Results from a prospective controlled single-blinded trial in 51 patients. *J Eur Acad Dermatol Venereol*. 2012;26:470-76.
19. Lee HI, Lim YY, Kim BJ, Kim MN, Min HJ, Hwang JH *et al*. Clinicopathologic efficacy of copper bromide plus/Yellow laser (578nm with 511nm) for treatment of melasma in Asian patients. *Dermatol Surg*. 2010;36:885-93.
20. Wanitphakdeedecha R, Manuskiatti W, Siriphukpong S, Chen TM. Treatment of melasma using variable square pulse Er:YAG laser resurfacing. *Dermatol Surg*. 2009;35:475-81.
21. Polnikorn N. Treatment of refractory melasma with the MedLite C6 Q-switched Nd:YAG laser and alpha arbutin: A prospective study. *J Cosmet Laser Ther*. 2010;12:126-31.
22. Suh KS, Sung JY, Roh HJ, Jeon YS, Kim YC, Kim ST. Efficacy of the 1064-nm Q-switched Nd: YAG laser in melasma. *J Dermatolog Treat*. 2011;22:233-38.
23. Wattanakrai P, Mornchan R, Eimpunth S. Low-fluence Q-switched neodymium-doped yttrium aluminum garnet (1064 nm) laser for the treatment of facial melasma in Asians. *Dermatol Surg*. 2010;36:76-87.
24. Prignano F, Ortonne JP, Buggiani G, Lotti T. Therapeutic approaches to melasma. *Dermatol Clin*. 2007;25:337-42.
25. Usuki A, Ohashi A, Sato H, Ochiai Y, Ichihashi M, Funasaka Y. The inhibitory effects of glycolic acid and lactic acid on melanin synthesis in melanoma cells. *Exp Dermatol*. 2003;12:43-50.
26. Sharquie KE, Al-Tikreety MM, Al-Mashhadani SA. Lactic acid as a new therapeutic peeling agent in melasma. *Dermatol Surg*. 2005;31:149-54.
27. Sharquie KE, Al-Tikreety MM, Al-Mashhadani SA. Lactic acid chemical peels as a new therapeutic modality in melasma in comparison to Jessner's solution chemical peels. *Dermatol Surg*. 2006;32:1429-36.
28. Ejaz A, Raza N, Iftikhar N, Muzaffar F. Comparison of 30% salicylic acid with Jessner's solution for superficial chemical peeling in epidermal melasma. *J Coll Physicians Surg Pak*. 2008;18:205-8.