

Effect of 30% salicylic acid peels in mild to moderate acne vulgaris: a hospital-based nonrandomised clinical study

Bava Aneesh, Joy Bifi, Anoop Thyvalappil, Sridharan Rajiv, Sreenivasan Ajayakumar, Mathew Pretty

Dermatology Department, Pariyaram Medical College, Kannur, Kerala, India

Abstract *Objective* To study the effect of 30% salicylic acid peels in mild to moderate acne.

Methods The study was conducted on patients visiting the dermatology outpatient department of a tertiary health care centre in South India. In 50 cases of mild to moderate acne vulgaris, 30% salicylic acid was applied in a predetermined manner for 5 minutes. Patients were reviewed once in two weeks up to 6 weeks with 3 sessions of peeling. Percentage reduction in acne severity index and total lesion count were noted to grade the effect of salicylic acid peel. Data collected was tabulated in a Microsoft Excel worksheet and a computer based analysis of the data was performed using SPSS software paired t test.

Results By the end of 6 weeks, excellent improvement in acne severity index was noted in 60% of cases and very good improvement in 30%. By the end of 6 weeks, excellent improvement in total lesion count was noted in 60% and very good improvement in 34%.

Conclusion Our study showed excellent to good improvement in most of patients. Our study showed that 30% salicylic acid peels can be considered as an important adjuvant therapy in mild to moderate acne with faster clinical response.

Key words

Acne vulgaris, chemical peel, salicylic acid.

Introduction

Acne vulgaris is known to be one of the common skin disease affecting adolescent and young adults with prevalence being nearly 80%.¹ Treatment of acne dates back to Egyptian times where sulphur was used, to recent time with various newer modalities of treatment with peeling and lasers.²

Since ancient times the concept of peeling the

skin was used to improve texture, to smoothen and beautify the skin. Cleopatra in ancient Egypt used sour milk, now known to contain lactic acid which is an alpha hydroxyl acid, while old wine containing tartaric acid was used by French women to enhance the appearance of skin.^{3,4}

Chemical peeling is the application of a chemical agent to the skin, causing controlled destruction of a part or entire epidermis, with or without the dermis, leading to exfoliation and removal of superficial lesions, followed by regeneration of new epidermal and dermal tissues. Chemical peeling has stood test of time as simple procedure, needing hardly any instrument to rejuvenate the skin, in spite of the

Address for correspondence

Dr. Anoop Thyvalappil
Dermatology Department,
Pariyaram Medical College, Kannur, Kerala.
India 670503.
Email: anooptvanoop@gmail.com

advent of various newer techniques.⁵

Salicylic acid (SA) peels are used as superficial peeling agent in various dermatological conditions.⁶ The lipophilicity of SA peels makes it to act on the superficial layers of the epidermis and sebaceous glands, which are hyperactive in acne. At higher concentration SA peels exfoliate only cornified cells of the epidermis and hair follicle without any inflammatory or degenerative changes, resulting in regeneration of the epidermis and papillary dermis. SA also has comedolytic and antiinflammatory action, making it suitable for both noninflammatory and inflammatory acne lesions.⁷

Methods

Fifty patients with mild to moderate acne, who did not take treatment for the same one month prior, were enrolled in study. This was a hospital-based nonrandomized clinical study, conducted on patients visiting the dermatology outpatient department of a tertiary health care centre in South India. Institutional ethical and research committee clearance was obtained. Assessment of patients general condition, mental status, skin condition (including sun exposure, skin type, keloid scars/ hypertrophic scars, infection) were done before the procedure. Serial digital photographs were taken for each patient under the standard settings with the written consent of patient after explaining the procedure, before first session as a baseline and then during each peel session and at the end of treatment during follow-ups. Severity of acne on face was graded at each visit according to the method of Burke and Cunliffe with individual scores added up.⁸ Four sites on face (chin, forehead, left and right cheek) were graded. The mean value from this grading was used for calculations. Total lesion count (TLC) was also done by taking total number of comedones, papules, pustules. Acne

lesions on other parts of body were not considered.

Acne Severity Index (ASI)=Papules+(2 x pustules)+(0.25xcomedones)

Total number of lesions for each patient was considered to be 100% at the first visit. Any subsequent decrease in number was calculated accordingly and graded as percentage of improvement. The mean of these improvement percentage was calculated for each group of patients and used for statistical analysis. Data was collected from the study sample using a pretested, structured questionnaire. Data collected from the patients were tabulated in a Microsoft Excel worksheet and a computer-based analysis of the data was performed using SPSS software paired t test.

30% SA was applied on to the face, starting from the forehead and progressing to the zygomatic cheeks, chin, upper lip, nose and lower eyelids, after degreasing the skin. The whole procedure was completed within 30 sec. The face was washed with water and patted dry after 5 minutes or early if intense erythema or burning sensation occurred. Patients were sent home with a moisturizer and instructed to limit sun exposure and use aqueous based sunscreens appropriately. Three sittings were done at 2 weeks interval. Clinical effect of peel evaluation was done in terms of percentage reduction of lesion. Count at each visit by taking TLC and ASI and effect of salicylic acid peel was further graded as excellent (>80% improvement), very good (66-80%), good (51-65%), fair (25-50%) and poor (<25%).

Results

Of the 50 patients with mild to moderate acne, 15 (30%) were males and 35 (70%) patients were females with female to male ratio 2.5:1. Most common age groups involved in acne

vulgaris in our study was 20-24 year (25 cases, 50%). Mean age of onset being 22.4 ± 5 year. All our patients belonged to Fitzpatrick's skin type IV and V.

History of associated stress as aggravating factor was seen in 29 (58%) patients. Out of 35 female patients, 6 (17%) patients had exacerbation of acne in premenstrual period. 31 (62%) patients had history of aggravation of acne lesions following intake of high glycemc diet. Fifteen (30%) patients had history of similar illness in family members. Four (8%) patients had erythema and 3 (6%) patients had burning sensation postpeel.

Out of 50 patients, 40 (80%) had grade 2 acne. The most common type of lesions in this study on day 1 was papules (mean count 14.5) followed by comedones (mean 9.1). By second week mean number of comedones were reduced to 4.6, papules to 8.2 and pustules to 1.1. By 4th week mean number of comedones was reduced to 2.9, papules to 4.9 and pustules to 0.3. By 6 weeks mean number of comedones was 1.2, papules 3.4 and pustules 0.2. Lesions were reduced to a statistically significant number by the end of 6 weeks with P value of 0.000.

Mean ASI and TLC at day 1 was found to be 22.5 and 26.4, respectively. The ASI further significantly reduced at 2 weeks, 4 weeks and 6 weeks to 11.6, 6.4 and 3.9, respectively with a statistical significant P value of 0.000 (**Figure 1**).

TLC also significantly reduced at 2 weeks, 4 weeks and 6 weeks to 13.9, 8 and 4.7 respectively with a statistical significant P value of 0.000 (**Figure 2**).

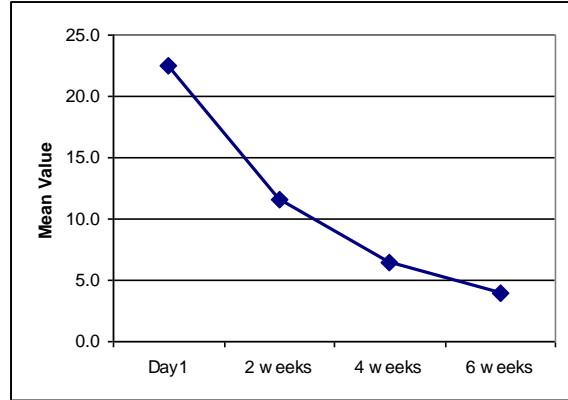


Figure 1 Comparison of Acne severity index (ASI) at different interval of time

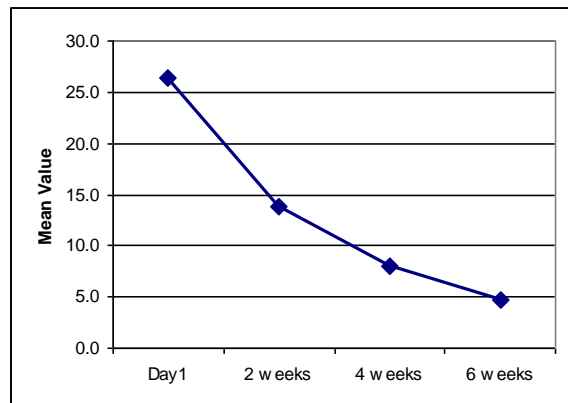


Figure 2 Comparison of Total lesional count (TLC) at different interval of time

Discussion

Chemical peeling is a simple office procedure that can be used in various dermatological conditions and can lead to excellent cosmetic improvement. SA peel is a superficial chemical peel and has been found to be safe and effective in darker skinned racial ethnic groups.⁹ Given the predictability, less downtime and efficacy compared with glycolic peels, salicylic acid peels have become more popular.

Out of 50 patients in our study, maximum number of patients i.e. 25 (50%) belonged to the age group of 20-24 years. The mean age at presentation in our study was 22.4 year. In our study 35 (70%) were female and 15 (30%) were males.

29 (58%) patient had aggravation of acne lesions during periods of stress. In the study by Pearl *et al.*¹⁰, 57.4% patients believed stress to be a contributing factor to acne. Green and Sinclair,¹¹ observed that 67% of students believed that stress played vital role in acne exacerbation. Emotional factors may affect acne by altering the pituitary-adrenal axis. Stress may be associated with increased adrenal androgen production and subsequent increase in sebum production.¹²

Out of 35 female patients, 6 (17%) patients had exacerbation of acne in premenstrual period. Khanna and Pandhi,¹³ noticed a mean increase in inflammatory lesions in premenstrual period, which decreased in postmenstrual period. Premenstrual flare is possibly related to a premenstrual change in the hydration of pilosebaceous epithelium. 31 (62%) patients gave history of taking high glycemic diet like fried food, chocolates, ice creams and milk with history of aggravation of acne lesions. In a study by Smith *et al.*¹⁴, there was a positive association between high glycemic diet and acne severity. Adebamowo *et al.*¹⁵ has reported a positive association between acne with intake of skimmed milk.

All our patients belonged to Fitzpatrick's skin type IV and V and tolerated the procedure very well, except for erythema in 4 (8%) patients and burning in 3 (6%) patients, which improved with mild topical steroid application. Study done by Lee and Kim⁷ showed erythema and burning in 8% of cases. Study by Hashimoto *et al.*¹⁶, 1 (18%) patient developed erythema following 30% salicylic acid peel. Study done by Garg *et al.*¹⁷ showed 17.3% of patients had burning sensation postpeel. Study done by Grimes⁹ showed that superficial peeling procedure is usually well tolerated in skin types III to VI.

The current study showed that SA peel was

effective in reducing both inflammatory and noninflammatory acne lesions ($P= 0.000$). Mean number of comedones decreased from 9.1 to 1.2 over a period of 6 weeks with 3 sittings of 30% SA with a stat ($P= 0.000$). Similarly mean number of papules and pustules reduced from 14.5 to 3.5 and 2.7 to 0.2 respectively over a period of 6 weeks with 3 sitting of salicylic acid peel. Study done by Kessler *et al.*¹⁸ showed, with SA peel at 2 month follow-up sustained decrease in number of acne lesions ($P< 0.01$).

At the end of 6 weeks 30 (60%) patients had shown excellent improvement, 15 (30%) patients had shown very good improvement, 3 (6%) had good improvement and 2 (4%) patients had fair improvement as per percentage change in ASI. As per percentage change in TLC at the end of 6 weeks, one patient (2%) had very good improvement, 15 (30%) patients had good improvement and 34 (68%) patients had fair improvement. These findings confirm the reports from previous studies by Rendon *et al.*¹⁹ Study done by Lee and Kim⁷ showed 77% of patients had good improvement with 30% SA peels.

A controlled double-blinded trial of 49 patients by Shalita²⁰ showed that SA helped in speedy resolution of both inflammatory and non inflammatory acne. Lee and Kim⁷ reported improvement in Korean patient with acne vulgaris treated with 30% SA peels and that the reduction in lesion count increased as duration of peel increased. They found that SA peeling was more effective in noninflammatory acne than inflammatory acne.

Another study by Joshi *et al.*²¹ where 30% SA peels were used in dark skinned patients with acne vulgaris, moderate to significant clearing of inflammatory acne lesions was seen in 89% of patients and reduction in comedones with a dramatic improvement after 6 sessions of 30%

SA peeling was reported.²¹

Kessler *et al.*²⁰ stated that patients demonstrated sustained clinical improvement of inflammatory and noninflammatory acne lesions with SA peeling sessions and for 2 months post-treatment with a good tolerability, faster than with traditional therapy. All patients with oily skin and enlarged pores had significant improvement. It may be due to the property of salicylic acid to inhibit microcomedone.

SA as peeling agent was evaluated to be safe, efficacious, and easy to administer. Compared to newer machine-based technologies for acne, chemical peeling is affordable with minimal downtime and can be performed in any dermatologists office.

Conclusion

Our study showed that 30% salicylic acid peels can be considered as an important adjuvant therapy in mild to moderate acne with faster clinical response and patient satisfaction and has shown to decrease both inflammatory and noninflammatory lesions of acne with minimal side effects. More randomized controlled clinical trials and comparative studies are needed to strengthen the currently available knowledge on the safety and utility of chemical peeling using salicylic acid in Indian patients.

References

1. Cunliffe WJ, Gould DJ. Prevalence of facial acne vulgaris in late adolescence and in adults. *Br Med J.* 1979;**1**:1190-1200.
2. Gupta AK, Nicol K. The use of sulphur in dermatology. *J Drugs Dermatol.* 2004;**3**:427-31.
3. Savant SS, editor. *Textbook of Dermatotomy and Cosmetology, 2nd edn.* Mumbai: ASCAD; 2005. p. 177-95.
4. Brody H, editor. *Chemical Peeling and Resurfacing, 2nd edn.* St. Louis: Mosby Year Book; 1997. p. 1-5.
5. Stegman SJ. A comparative histologic study of the effects of the three peeling agents and dermabrasion on normal and sun damaged skin. *Aesth Plast Surg.* 1982;**6**:123-35.
6. Kligman D, Kligman AM. Salicylic acid peels for the treatment of photoaging. *Dermatol Surg.* 1998;**24**:325-8.
7. Lee HS, Kim IH. Salicylic acid peels for treatment of acne vulgaris in Asian patients. *Dermatol Surg.* 2003;**29**:1196-9.
8. Burke BM, Cunliffe WJ. The assessment of acne vulgaris: The Leeds technique. *Br J Dermatol.* 1984;**111**:83-92.
9. Grimes PE. The safety and efficacy of salicylic acid peels in darker racial ethnic groups. *Dermatol Surg.* 1999;**25**:18-22.
10. Pearl A, Arnold B, Birchall NM, Birchall NM. The impact of acne: a study of adolescent attitudes, perceptions and knowledge. *NZ Med J.* 1998;**111**:265-71.
11. Green J, Sinclair RD. Perceptions of acne vulgaris in final year medical student written examination answers. *Austral J Dermatol.* 2001;**42**:98-101.
12. Cohen BA, Prosen P, Schachner AL. Acne. In: Schachner AL, Hansen CR, editors. *Paediatric Dermatology, 2nd edn, Vol 2.* New York: Churchill Livingstone; 1995. p. 661-83.
13. Khanna VN, Pandhi KR. Relationship of acne with menstrual period. *Indian J Dermatol Venereol Leprol.* 1991;**57**:138-40.
14. Smith RN, Mann NJ, Braue A, Mäkeläinen H, Varigos GA. A low glycemic load diet improves symptoms in acne vulgaris patients: a randomized controlled trial. *Am J Clin Nutr.* 2007;**86**:107-15.
15. Adebamowo CA, Spiegelman D, Berkey CS, Danby FW, Rockett HH, Colditz GA *et al.* Milk consumption and acne in adolescent girls. *Dermatol Online J.* 2006;**12**:1.
16. Hashimoto Y, Suga Y, Mizuno Y, Hasegawa T, Matsuba S, Ikeda S *et al.* Salicylic acid peels in polyethylene glycol vehicle for treatment of comedogenic acne in Japanese patients. *Dermatol Surg.* 2008;**34**:267-9.
17. Garg VK, Sinha S, Sarkar R. Glycolic acid peels versus salicylic mandelic acid peels in active acne vulgaris and post acne scarring and hyper pigmentation: A comparative study. *Dermatol Surg.* 2009;**35**:59-65.
18. Kessler E, Flanagan K, Chia C, Rogers C, Glaser DA. Comparison of alpha and beta hydroxy acid chemical peels in the treatment

- of mild to moderately severe facial acne vulgaris. *Dermatol Surg*. 2008; **34**: 45-50.
19. Rendon MI, Berson DS, Cohen JL, Roberts WE, Starker I, Wang B. Evidence and considerations in the application of chemical peels in skin disorders and aesthetic resurfacing. *J Clin Aesthet Dermatol*. 2010;**7**:32-43.
20. Shalita AR. Treatment of mild to moderate acne vulgaris with salicylic acid in an alcohol-detergent vehicle. *Cutis*. 1981;**28**(5): 556-8.
21. Joshi SS, Boone SL, Alam M, Yoo S, White L, Rademaker A *et al*. Effectiveness, safety, and effect on quality of life of topical salicylic acid peels for treatment of post inflammatory hyper pigmentation in dark skin. *Dermatol Surg*. 2009; **35**: 638-44.