

Efficacy of topical tacrolimus 0.1% and clobetasol propionate 0.05% in the treatment of alopecia areata

Md. Shakhawat Hossain*, Md. Titu Miah*, Md. Zulfiquir Hossain Khan*, Lubna Khondker**, Md Rashidul Hasan**

* Dermatology Department, Dhaka Medical College Hospital, Dhaka, Bangladesh

** Dermatology Department, Bangabandhu Sheikh Mujib Medical University, Dhaka, Bangladesh

Abstract

Objective To assess the efficacy of tacrolimus and clobetasol propionate in the treatment of alopecia areata.

Methods A clinical trial was carried out in the department of Dermatology and Venereology, Dhaka Medical College Hospital, Dhaka, Bangladesh from May 2013 to April 2014. Total sixty patients were enrolled and divided into group A and group B. Thirty of group A patients were treated with topical tacrolimus and thirty of group B patients were treated with topical clobetasol propionate.

Results In group A, the duration of illness ranged from 2 months to 36 months and in group B, from 1 month to 24 months. Among the patients of group A and B, 25 (83.3%) and 27 (90%) patients improved, respectively. After 16th week of treatment, slight response in 6 (20%) and 4 (13.3%) and moderate response in 18 (59.4%) and 22 (63.2%) and marked response in 1 (3.3%) and 1 (3.3%) was seen in group A and group B, respectively. No significant difference was observed (p value = 0.648).

Conclusion Both the drugs, clobetasol propionate and tacrolimus when used individually, were found to be equally effective in the treatment of alopecia areata and tacrolimus ointment 0.1% can be used as an alternate therapeutic modality.

Keywords

Efficacy, tacrolimus, clobetasol propionate, alopecia areata.

Introduction

Alopecia areata (AA) is a disease characterized by hair cycle dysfunction and the presence of peribulbar and perifollicular mononuclear cell infiltrate.¹ The majority of patients report the rapid onset of one or several well-defined, usually round, 1 to 4 cm areas of scalp hair loss. A common feature is the presence of “exclamation-mark” hairs that are broken and

short hairs that taper proximally.^{2,3} Some patients with AA also exhibit nail pitting.⁴ The disease may affect any hair-bearing area, but most commonly affects the scalp, eyebrows, eyelashes, and beard. Hair loss may be patchy or extensive.⁵ In extreme cases, the disease may result in total loss of scalp hair (alopecia totalis) or scalp and body hair (alopecia universalis).⁶ Although the etiology of AA is unknown, most evidence supports the hypothesis that the disease is immunologically-mediated.⁷ AA is a common yet challenging condition to manage in the dermatology.⁸ For limited scalp AA, intralesional corticosteroid therapy is considered as the drug of choice by many experts.⁹ Local application of potent topical corticosteroids has

Address for correspondence

Dr. Lubna Khondker,

Assistant Professor

Dept of Dermatology and Venereology,

BSMMU, Dhaka, Bangladesh.

E-mail: lubnaderma@gmail.com

been effective in the treatment of moderate-to-severe AA. Folliculitis is a common side effect to topical corticosteroids. Telangiectasia and atrophy may develop rarely.¹⁰ However, limited efficacy and local, as well as, systemic side-effects, especially in long-term therapy, are the main drawbacks of these strategies and restrict their use. Tacrolimus, a nonsteroidal topical immunomodulator, may be effective treatment for a variety of inflammatory skin disorders such as alopecia areata.¹¹

There are different treatment options available for patients with alopecia areata. All approaches have advantage and disadvantages and none is appropriate for every patient.¹⁰ Clinical efficacy of topical corticosteroids in AA is still controversial. This study aimed to compare efficacy of clobetasol with tacrolimus in AA.

Methods

A clinical trial was conducted from May 2013 to April 2014 and patients of AA attending the outpatient department of Dermatology and Venereology, Dhaka medical College, Dhaka during the study period were enrolled in the study. Convenient type of purposive sampling was the sampling technique. Inclusion criteria were: 1) patients of asymptomatic, non-scarring, patchy hair loss over scalp and elsewhere, 2) patients age range 12 to 50 years, 3) patients of both sexes, 4) patient who never received treatment for hair loss, and 5) patients who gave informed consent to comply with the study procedure. Exclusion criteria were: 1) patients with pregnancy, lactating mothers, 2) extensive (more than 3 patches) or atypical alopecia areata (alopecia totalis, alopecia universalis, diffuse), and 3) history of allergy to glucocorticoids or tacrolimus.

In total, 60 patients of AA were enrolled and divided into group A and group B. Thirty of

group A patients were treated with topical tacrolimus 0.1% and 30 of group B patients were treated with topical clobetasol propionate 0.05%, twice daily application for 12 weeks. At the patient's first visit, a careful medical history and a good physical examination were carried out, including an examination of all hair-bearing areas and nails. Full information about disease, including the relapsing nature of AA, prognosis, and risk/benefit ratio of treatment options, was provided to patients or their gurdians in easily understandable local language and then informed written consent were taken from each patient or their gurdians.

Data were collected by face to face interview and were recorded in a questionnaire. Baseline laboratory investigations were carried out for purpose of exclusion and monitoring of side effects. Laboratory investigations included complete blood count, serum ALT, serum creatinine, random blood sugar and anti-thyroid antibodies, antinuclear antibodies and total IgE levels.

The effect of treatment was evaluated using photographs of the patients before and after the study and clinical evaluation of patients. The clinical response were evaluated at 4 weeks, 8 weeks and 12 weeks after completion of therapy and clinical comparison were done in each follow-up visit and at the end of the treatment. Laboratory investigations were evaluated at 4 weeks, 8 weeks and 12 weeks after completion of therapy in all patients. Improvement was graded as excellent (>75% improvement), marked (51% to 75%), moderate (26% to 50%) and slight (25% or less improvement).

Data analysis was performed by Statistical Package for Social Science (SPSS), version-16. Data was edited, coded and entered into the computer. Statistical analysis was done and level of significance was measured by using

appropriate procedures like chi-square test (χ^2). Level of significance (p value) was set at 0.05 and confidence interval at 95%.

Results

Table 1 shows age distribution of two groups. In group A, 8 (26.7%) patients were ≤ 15 years and 22 (73.3%) were > 15 years, whereas in group B, 7 (23.3%) patients aged ≤ 15 years and 23 (76.7%) > 15 years (χ^2 value = 0.089, df = 1, $p = 0.766$), insignificant difference in two groups (> 0.05). In group A, the duration of illness ranged from 2 months to 36 months, with a mean of 10 months. In group B, the duration of illness ranged from 1 month to 24 months, with a mean of 8.20 months (t value = 1.010, $p = 0.316$, insignificant difference). Regarding the number of lesions, both groups showed similar number of lesions. Single lesion was present in 15 (50%) patients for group A and 14 (46.7%) in group B. Multiple lesions were seen in 15 (50%) and 16 (53.6%), respectively in group A and group B, χ^2 value = 0.067, df = 1, $p = 0.796$, insignificant difference).

Figure 1 shows the recovery rate after treatment. In group A and B, 25 (83.3%) and 27 (90%) improved, respectively. The numbers of failure were 5 (16.7%) and 3 (10%) for group A and group B, respectively (χ^2 value = 0.577, df = 1, $p = 0.448$, insignificant).

Table 2 compares the clinical response in two groups. After 16th week of treatment, slight response was seen in 6 (20%) and 4 (13.3%) patients, moderate response in 18 (59.4%) and 22 (63.2%) and marked response in 1 (3.3%) and 1 (3.3%) in group A and group B, respectively ($p = 0.648$, insignificant difference).

Table 1 Distribution of age among study groups (with χ^2 test significance)

	Group A n (%)	Group B n (%)	Total
<i>Age (years)</i>			
≤ 15	08 (26.7)	07(23.3)	15 (25.0)
> 15	22 (73.3)	23(76.7)	45 (75.0)*
<i>Duration of illness (months)</i>			
Range	2-36	1-24	1-36
Mean	10.00 \pm 7.24	8.20 \pm 6.54	9.10 \pm 6.90*
<i>Number of lesions</i>			
Single	15 (50)	14 (46.7)	29 (48.3)*
Multiple	15 (50)	16(53.3)	31(51.7)

$p > 0.05$, insignificant.

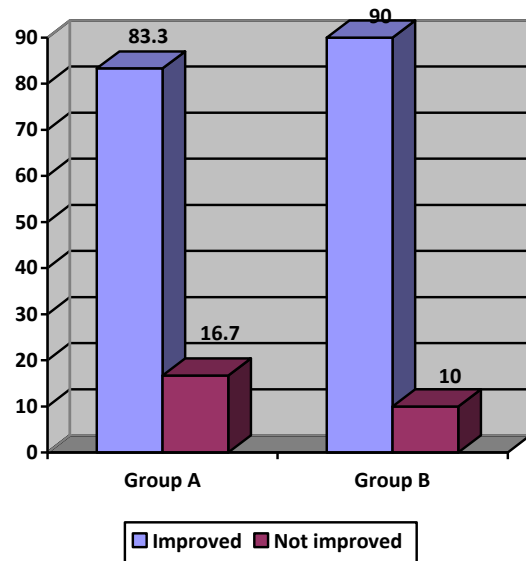


Figure 1 Distribution of recovery rate among the study groups(n=60)

Table 2 Comparison of improvement in two groups after 16 weeks.

Grades of response	Group A n(%)	Group B n (%)
Slight	6 (20.0)	4 (13.3)
Moderate	18 (59.4)	22 (63.2)
Marked	1 (3.3)	1 (3.3)
Excellent	0 (0)	0 (0)

Slight (<25% improvement), moderate (26% to 50% improvement), marked (51% to 75% improvement), and excellent response (>75% improvement). X^2 value = 0.867, $p = 0.648$.

Discussion

In our study, thirty of group A patients were treated by topical tacrolimus 0.1% and thirty of group B patients were treated by topical

clobetasol propionate 0.05%. Regarding age distribution of two groups, the majority was more than 15 years of age in both groups. Duration of disease was also comparable in two groups.

In group A and B, 25 (83.3%) and 27 (90%) patients improved, respectively. The number of failures was 5 (16.7%) and 3 (10%) for group A and group B, respectively. After 16th week of treatment, slight response was seen in 6 (20%) and 4 (13.3%) patients and moderate response in 18 (59.4%) and 22 (63.2%) patients and marked response was seen in 1 (3.3%) patient each in group A and group B, respectively. These findings are similar to those of Saleem *et al.*¹³, Tosti *et al.*^{10,11,14} and Sotiriou *et al.*¹²

Saleem *et al.*¹³ carried out a clinical trial with total of 60 patients having patchy alopecia areata. The patients were assigned to either betamethasone valerate 0.1%, tacrolimus 0.03% or soft paraffin to be applied to the affected areas twice daily for 12 weeks followed by monthly follow-up visits. The baseline assessment of alopecia grading was performed using a 6-point scale score: S0 = no alopecia, S1 = hair loss <10%, S2 = hair loss 11-25%, S3 = hair loss 26-50%, S4 = hair loss 51-75% and S5 = hair loss >75%. The primary study outcome was to compare the hair regrowth rate. Efficacy was evaluated using a hair regrowth score (RGS) with a scale ranging from 0 (regrowth < 10%) to 1 (11-25%), 2 (26-50%), 3 (51-75%) and 4 (regrowth >75%). At week 12, the RGS was 3.55±0.11 in betamethasone group ($p<0.001$), 2.2±0.15 in tacrolimus group ($p<0.005$) and 0.85±0.08 (ns) in control group, respectively. At week 12, a complete or nearly complete regrowth rate in Betamethasone group (i.e. RGS>3) was observed in 70 % (14/20) of patients, as compared to 45% (9/20) of patients in tacrolimus group and RGS >3 was not observed in any of the patient of control group.¹³

Tosti *et al.*¹⁴ carried out a 24-week trial with thirty-four patients with moderate to severe AA (eight men, mean age 40±13 years). Clobetasol foam (CF) and the corresponding placebo foam (PF) were applied twice a day for 5 days/week for 12 weeks (phase 1) using an inpatient design (right vs. left). From weeks 13 to 24 each enrolled patient continued only with the treatment (both on the right and left site) that was judged to have a greater efficacy than that on the contralateral side (phase 2). The primary outcome of the trial, evaluated on an intention-to-treat basis, was the hair regrowth rate, which was evaluated using a semiquantitative score (RGS) (from 0: no regrowth, to 4: regrowth of 75%). At baseline the AGS was 4.1 (range: 2-5). Nine (26%) patients prematurely concluded the trial. At the end of phase 1, a greater hair regrowth was observed in 89% of the head sites treated with CF vs. 11% in the sites treated with PF. The RGS was 1.2±1.6 in the CF-treated sites and 0.4±0.8 in the PF-treated sites ($P=0.001$). A RGS of 2 (hair regrowth of more than 25%) was observed in 42% CF-treated sites and in 13% of PF-treated sites ($p=0.027$). In seven subjects (20%) a RGS of 3 to 4 (hair regrowth of 50%) was observed in CF-treated sites. In three subjects (9%) a RGS of 4 (hair regrowth of 75%) was observed in CF-treated sites. In one patient only, in a PF-treated region, a RGS of 3 was observed. The AS was reduced to 3.8 by CF treatment at the end of phase 1 and to 3.3 at the end of phase 2 ($p=0.01$). From weeks 12 to 24 the treatment with CF induced a further increase in the RGS (from 1.2 to 1.5±1.4). Forty-seven per cent of CF-treated patients had a RGS of 2 at the end of the trial.¹⁴

Tosti *et al.*¹⁰ conducted a study with alopecia areata totalis (AT) or AT/alopecia universalis. A total of 28 patients were instructed to apply 2.5 g of clobetasol propionate to the right side of the scalp every night under occlusion with a plastic film. Treatment was performed 6 days a week

for 6 months. When regrowth of terminal hair occurred, treatment was extended over the entire scalp. All patients were followed up for another 6 months. Of the 28 patients included in the study, 8 (28.5%) were treated successfully. Regrowth of terminal hair began on the treated side 6 to 14 weeks after the start of treatment. Of these 8 patients, 3 had a relapse and were not able to maintain hair regrowth. Their study showed that clobetasol propionate 0.05% under occlusion is effective in inducing hair regrowth in patients with AT or AT/alopecia universalis. Occurrence of hair regrowth only on the treated half of the scalp clearly shows that efficacy of treatment is a result of a local and not systemic effect of the drug.¹⁰

Sotiriou *et al.*¹⁵ carried out a study with 14 patients of 5 to 12 years of age, in order to initially assess the efficacy of tacrolimus ointment 0.1% in the treatment of patchy alopecia areata of the scalp. Patients applied the ointment twice daily for six months. Five out of eleven patients (45%) showed significant hair regrowth. Their results showed that tacrolimus ointment 0.1% may be an alternate therapeutic modality for short-standing, patchy and small-diameter lesions of alopecia areata in children.¹⁵

Conclusion

Both the drugs, clobetasol propionate and tacrolimus when used individually, were found to be equally effective in the treatment of alopecia areata. Further multicenter, randomized, double-blind study should be conducted with large sample size

References

1. Alsantali A. Alopecia areata: a new treatment plan. *Clin Cosmet Investig Dermatol.* 2011;**4**:107-15.
2. Tan E, Tay YK, Glam YC. A clinical study of childhood alopecia areata in Singapore. *Pediatr Dermatol.* 2002;**19**:298-301.
3. Tosti A, Bellavista S, Iorizzo M. Alopecia areata: A long term follow-up study of 191 patients. *J Am Acad Dermatol.* 2006;**55**:438-41.
4. Galán-Gutiérrez M, Rodríguez-Bujaldón A, Moreno-Giménez JC. Update on the treatment of alopecia areata. *Actas Dermosifiliogr.* 2009;**100**:266-76
5. Wang E, Lee JS, Tang M. Current treatment strategies in pediatric alopecia areata. *Indian J Dermatol.* 2012;**57**:459-65.
6. García Hernández MJ, Camacho Martínez F. Epidemiología clínica de la alopecia areata. *Actas Dermosifiliogr.* 2002;**93**:223-8.
7. MacDonald Hull SP, Wood ML, Hutchinson PE *et al.* British Association of Dermatologists. Guidelines for the management of alopecia areata. *Br J Dermatol.* 2003;**149**:692-9.
8. Mandani S, Shapiro J. Alopecia areata update. *J Am Acad Dermatol.* 2000;**42**:549-66.
9. Ferrando J, Moreno-Arias GA. Multi-injection plate for intralesional corticosteroid treatment of patchy alopecia areata. *Dermatol Surg.* 2000;**26**:690-1.
10. Tosti A, Piraccini BM, Pazzaglia M, Vincenzi C. Clobetasol propionate 0.05% under occlusion in the treatment of alopecia totalis/universalis. *J Am Acad Dermatol.* 2003;**49**:96-8.
11. Tosti A, Guidetti MS, Bardazzi F, Misciali C. Long-term results of topical immunotherapy in children with alopecia totalis or alopecia universalis. *J Am Acad Dermatol.* 1996;**35**:199-201.
12. Price VH, Willey A, Chen BK. Topical tacrolimus in alopecia areata. *J Am Acad Dermatol.* 2005;**52**:138-9.
13. Saleem A, Khan M, Mashori GR *et al.* Comparison of effectiveness of topical tacrolimus and betamethasone with soft paraffin in the treatment of patchy alopecia areata. *Pak J Med Sci.* 2009;**25**:833-6.
14. Tosti A, Iorizzo M, Botta GL, Milani M. Efficacy and safety of a new clobetasol propionate 0.05% foam in alopecia areata: a randomized, double-blind placebo-controlled trial. *J Eur Acad Dermatol Venereol.* 2006;**20**:1243-7.
15. Sotiriou E, Patsatsi A, Fotiadou C *et al.* Tacrolimus ointment 0.1% in the treatment of active patchy alopecia areata of childhood. *Eur J Pediatr Dermatol.* 2007;**17**: 227-30.