

Bullous pemphigoid treated with dexamethasone-cyclophosphamide pulse therapy

Ramji Gupta

Department of Dermatology, Indraprastha Apollo Hospital, Sarita Vihar, New Delhi, India

Abstract *Objective* To induce permanent remission in bullous pemphigoid patients.

Methods 5 patients of bullous pemphigoid treated with dexamethasone-cyclophosphamide pulse (DCP) therapy are being reported. Diagnosis was confirmed by histopathology and immunofluorescence test. Each pulse comprised of dexamethasone 100 mg dissolved in 500 ml of glucose and transfused intravenously over 1-1.5 hours on three consecutive days. On 2nd day cyclophosphamide 500 mg was transfused through the same drip. It was repeated every 28 days. In between oral cyclophosphamide 50mg daily was given. The whole treatment was divided into 4 phases: phase I, till all the lesions cleared; phase II, no lesions but still DCP was given for 9 months; phase III DCP withdrawn, only oral cyclophosphamide 50mg daily was given for 9 months; and in phase IV, all the treatment was withdrawn and patients are followed-up as much as possible. Period of remission was noted.

Results Out of five, three patients entered into remission up to 7.5 years after stoppage of all treatment. Remaining two are in remission for one to two years.

Conclusion Dexamethasone-cyclophosphamide pulse therapy is able to induce permanent remission in bullous pemphigoid.

Key words

Bullous pemphigoid, dexamethasone-cyclophosphamide pulse therapy, DCP.

Introduction

Bullous pemphigoid is a disease of tense bullae usually found in elderly and sometimes associated with itching and malignancy.

Dexamethasone-cyclophosphamide pulse (DCP) therapy was introduced by Pasricha and Gupta in 1982 to treat Reiter's disease.¹ Subsequently, it was used to treat pemphigus,²⁻⁴ SLE,⁵ systemic sclerosis,^{6,7} pyoderma gangrenosum,⁸ lichen amyloidosis,⁹ Peyronie's disease,¹⁰ prurigo nodularis¹¹ and also rheumatoid arthritis.¹²

Address for correspondence

Dr. Ramji Gupta
Department of Dermatology, Indraprastha
Apollo Hospital,
Sarita Vihar, New Delhi, India
Email: drramjigupta@yahoo.co.in

This paper reports 5 patients of bullous pemphigoid treated with DCP therapy.

Methods

Five patients of bullous pemphigoid treated with DCP has been reported. (Table 1) Diagnosis was made on the basis of clinical, histopathological and immunofluorescence tests.

Before starting DCP therapy, patients were tested for hemoglobin, erythrocyte sedimentation rate, total and differential leucocyte count, platelets count, serum creatinine, serum glutamic oxaloacetic transaminase (SGOT), serum glutamic pyruvic transaminase (SGPT) and blood sugar levels.

Table 1 Details of bullous pemphigoid patients treated with dexamethasone cyclophosphamide pulse therapy

No.	Age/Sex	Duration before treatment	Lesions of pemphigoid Skin	Additional Treatment	I	II	III	IV	Biopsy Sub epidermal Bullae	IIF	DIF
1	80/M	3M	+	4mg dexa daily X15days	3	9	9	7.5 Y	+	C ₃	IgG
2	61/M	15 day	+	-	1	9	9	1 Y 9 M	-	C ₃	IgG
3	61/M	2.5M	+	-	1	9	9	1 Y 5 M	+	ND	IgG
4	51/M	2 Y	+	-	3	2	-	7 M	+	ND	ND
5	51/F	2 M	+	1 Mid Pulse for 2 days	2	-	-	1 Y	+	C ₃	IgG

MP=Mid pulse, dexamethasone 100 mg for 2 day, ND= Not done, M=Month, Y=year, IIF=Indirect immunofluorescence test, DIF=Direct immunofluorescence test

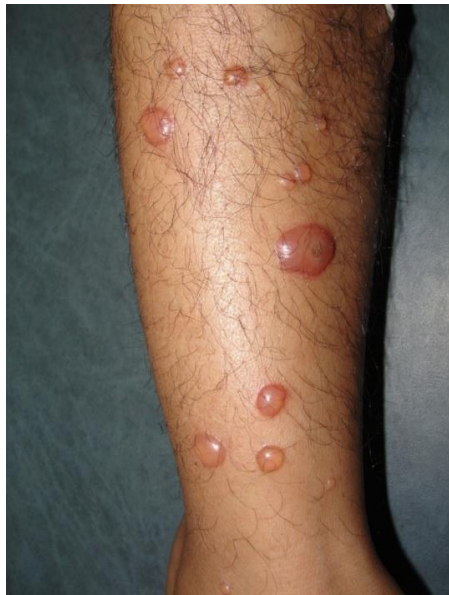

Figure.1 Tense Bullae Pemphigoid leg in case -1

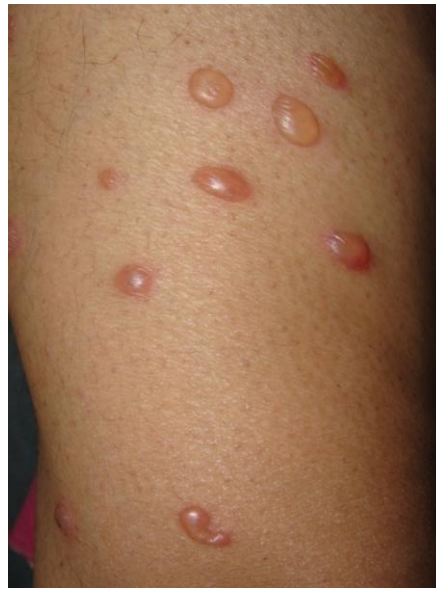

Figure.2 Tense Bullae Pemphigoid abdomen in case -2

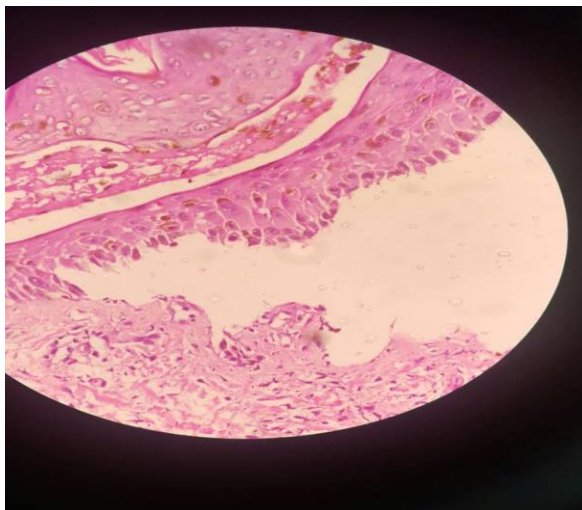


Figure 3 Subepidermal bullae in H&E stain X40.

Dexamethasone-cyclophosphamide pulse was started which consists of dexamethasone 100 mg given intravenously in 500ml of 5% glucose solution for 3 consecutive days. On second day cyclophosphamide 500 mg was given from the same drip. It was repeated every 28 days. In between cyclophosphamide 50mg orally was given. The regimen was divided into 4 phases. In phase I, DCP was given till all the lesions cleared. In phase II, DCP was given for 9 months. In phase III, DCP was stopped and the patient received only oral cyclophosphamide 50mg daily for 9 months. If there was no recurrence, patient enter into phase IV where all

the drugs were stopped and patients were followed up as long as possible.

Case 1

An 80-year-old male presented with tense blisters (**Figure 1**) all over his body since 3 months. Direct immunofluorescence test for IgG at basement membrane zone was positive. Histopathology showed subepidermal split. A diagnosis of bullous pemphigoid was made and DCP was started. Patient entered into phase II after receiving 3 DCPs. Subsequently, he was given 9 DCPs in phase II and only oral cyclophosphamide 50 mg daily for 9 months in phase III. He entered into phase IV on 13.2.2010. Since then he has not developed any blister till now.

Case 2

A 61-year-old male developed clear tense vesicles with itching on different parts of the body (**Figure 2**) with infection on hands and feet of 15 days duration. Lesions improved with systemic antibiotics in 8 days. Biopsy of the blister showed linear deposits of IgG and C3 at the basement membrane zone. DCP was started, his lesions cleared in one month (phase I). Subsequently, he received 9 DCPs in phase II and only cyclophosphamide 50mg daily in phase III. His cyclophosphamide was stopped on 30 August 2014. Since then there is no recurrence of his diseases.

Case 3

A 61-year-old male presented with recurrent tense vesicles of 2½ year duration with infection on the leg. Infection improved with systemic antibiotics in 10 days. Histopathology of the lesions showed subepidermal bullae (**Figure 3**) with direct immunofluorescence showing IgG at the basement membrane zone. He received 1

DCP in phase I, 9 DCP in phase II, and cyclophosphamide 50 mg alone in phase III for 9 months, which was stopped on 1st December, 2014. Since then there is no recurrence.

Case 4

A know diabetic of 13-year duration developed sudden, erythematous, itchy eruptions mostly on the palms and thighs. Oral betamethasone 4 mg daily was started. Lesions improved but developed tense blisters on the hands, thighs and abdomen 10 days after reducing the betamethasone. Biopsy from hand was consistent with bullous pemphigoid. He was started DCP and lesions started subsiding. Three pulses cleared all the lesions in 10 days (phase I). He took 4 more DCP in phase II and stopped further DCP in December 2016 without any recurrence. Subsequent follow-up without any DCP showed no recurrence till now (6 months).

Case 5

A 57-year female diabetic of 8-year duration developed tense blisters all over her body. She was started oral betamethasone 8 mg daily when she was referred to us. Her immunofluorescence showed linear deposits of C3 and IgG at dermoepidermal junction along with subepidermal bullae containing fibrous exudates. She was started DCP with mild improvement. Dexamethasone intravenous 100 mg alone was given on 2 consecutive days after 15 days (mid pulse). All lesions cleared in about 8 days. Betamethasone was reduced slowly and stopped in 10 days 2nd DCP was given which led to clearance of all the lesions (phase I, 2 DCPs). She continued 50 mg cyclophosphamide and was given 1st pulse of phase II with no lesions. After that she stopped DCP and switched on to nicotinamide 100mg daily by other dermatologist. She is continuing the same till now without any lesions.

Results

All the 5 patient went to remission with DCP. 3 patients were followed up from 1.5 to 7.5 years with no relapse. While 2 patients enter into phase II but could not be followed up because they stopped coming. No serious side effects were reported in all five patients.

Discussion

One can think of bullous pemphigoid in an old patient with tense blisters. Sometimes itching is also part of the disease. For treatment many drugs are available like systemic immunosuppressives, like oral corticosteroids, azathioprine, cyclophosphamide, methotrexate, cyclosporin A, combined tetracycline/minocycline with nicotinamide, mycophenolate mofetil, dapson and biologics like anti-TNF drugs, rituximab, IVIG and plasma exchange which lead to disease remission in 6-9 months remission.¹³ With most of these medicines follow-up was very limited. We followed up to 7.5 years then it can be presumed that DCP has cured the disease. Appelhans *et al.*¹⁴ in a very short follow-up of 6 months reported 7 bullous pemphigoid cases while treating 20 patients of bullous auto-immune dermatoses with DCP. In our group, 3 patients were followed up from 1.5-7.5 years while 2 could not complete the treatment but stopped coming after they entered into phase II i.e. they both had been free from the lesions. One patient after completing phase I with 3 pulses took 2 more pulses from outside due to distance and was free from the lesions since December 2016. Second patient took 3 pulses and 1 midpulse after first pulse. Midpulse was given when disease was serious and only given for 2 days without cyclophosphamide on day 2. After 3rd pulse she stopped pulse and changed to nicotinamide 100mg daily which she was still taking without any recurrence since June 2016

DCP is very safe to use even in elderly people in whom bullous pemphigoid is very common.

References

1. Pasricha JS, Gupta R. Pulse therapy with dexamethasone in Reiter's disease (A case report). *Indian J Dermatol Venereol Leprol.* 1982;**48**:358-61.
2. Pasricha JS, Gupta R. Pulse therapy with dexamethasone cyclophosphamide in pemphigus. *Indian J Dermatol Venereol Leprol.* 1984;**50**:199-203.
3. Gupta R. Prolonged remission of pemphigus induced by dexamethasone cyclophosphamide pulse therapy. *Indian J Dermatol Venereol Leprol.* 2007;**73**:121-3.
4. Gupta R, Gupta S, Gupta A. Efficiency and safety of dexamethasone cyclophosphamide pulse therapy in the treatment of pemphigus – An open randomized controlled study. *Apollo Medicine.* 2015;**12**:243-7.
5. Gupta R, Gupta S, Khera V. Systemic lupus erythematosus response to dexamethasone – cyclophosphamide pulse therapy. *J Dermatolog Treatment* 2008; **20**:55-8
6. Pasricha JS, Ramam M, Shah S. Reversal of systemic sclerosis with dexamethasone pulse therapy. *Indian J Dermatol Venereol Leprol.* 1990;**56**:40-2.
7. Gupta R. Systemic sclerosis treated with dexamethasone pulse therapy. *Indian J Dermatol Venereol Leprol.* 2003;**69**:191-2.
8. Pasricha JS, Reddy R, Nandakishore T, Khera V. Pyoderma gangrenosum treated with dexamethasone pulse therapy. *Indian J Dermatol Venereol Leprol.* 1991;**57**:225-8.
9. Gupta R, Gupta S. Dexamethasone cyclophosphamide pulse therapy in lichen amyloidosis : A case report. *J Dermatolog Treat.* 2007;**18**:249-51.
10. Gutpa R, Gupta S. Peyronie's disease treated with oral weekly dexamethasone and continuous low dose cyclophosphamide. *Indian J Dermatol Venereol Leprol.* 2014;**59**:317.
11. Gupta R. Treatment of prurigo nodularis with dexamethasone-cyclophosphamide pulse therapy. *Indian J Dermatol Venereol Leprol.* 2016;**82**:239-41.
12. Gupta R. Prolonged remission of rheumatoid arthritis with dexamethasone-cyclophosphamide pulse therapy: A case series. *Indian J Rheumatol.* 2014;**2**:98-100.

13. Khandpur S, Verma P. Bullous pemphigoid. *Indian J Dermatol Venereol Leprol*. 2011;**77**:450-5.
14. Appelhans M, Bonsman S, Orge C, Bröcker EB. Dexamethasone-cyclophosphamide pulse therapy in bullous auto-immune dermatology. *Hautarzt*. 1993;**44**:143-7.