

Case Report

Familial porokeratosis of Mibelli: A peerless entity

Yugandar Inakanti

Department of DVL, P.E.S. Institute of Medical Sciences and Research, Kuppam, AP, India

Abstract Porokeratosis are a group of hereditary or acquired disorders characterized by annular plaques with an atrophic centre and a hyperkeratotic peripheral ridge. Pathologically, porokeratosis is characterized by a column of parakeratotic cells, called the cornoid lamella. This report describes a 55-year-old male with his two sons affected by porokeratosis of Mibelli and it was confirmed histopathologically. The rarity of this disorder in family, its clinical exuberance and the destructive character of the lesions, as well as, nasal, finger and abdomen involvement were unusual in case of porokeratosis.

Key words

Ala nasi, cornoid lamella, finger, parakeratosis, porokeratosis.

Introduction

Porokeratosis include a group of heterogeneous disorders that represent diverse phenotypic expressions of the same genetic defect, which is mainly inherited in an autosomal dominant form.¹

It was first described by Mibelli in 1893 who described atrophic patches clinically and histological cornoid lamella. These lesions are most commonly found on the extremities, but can also be found on genitalia, face, oral mucosa and cornea.² Though the patches are generally asymptomatic they can often lead to ulcerative, verrucous, giant, and malignant lesions.³

However, as noted by Sybert (2010), the existence of several families with expression of more than one variant of porokeratosis among members, and individuals expressing more than one variant of porokeratosis. We

described a case of porokeratosis of Mibelli at unusual sites in one family.

Case report

A 55-year-old male, married, born of consanguineous parents, presented with skin lesions over abdomen. He had been suffering from multiple annular plaques and papules over body for 20 years. The lesions were slowly progressive with no signs of self-healing.

First son aged 32 years complained of multiple skin lesions over nose for 5 years. He had past history of lesions over face. Second son aged 29 years complained of single skin lesion over finger since 1 year. They had been normal physical milestones of development as a child. They appeared to be immunocompetent with no history of recurrent infections or any other skin lesions.

The physical examinations of patients were within normal limits. On systemic examination no abnormality was revealed. Clinically there was no evidence of sexually transmitted diseases and laboratory investigations were within normal limits.

Address for correspondence

Dr. Yugandar Inaacs,
Department of DVL
P.E.S. Institute of Medical Sciences and
Research
Kuppam -517425, Chittoor District,
Andhra Pradesh, India
Email: dryugandar@gmail.com

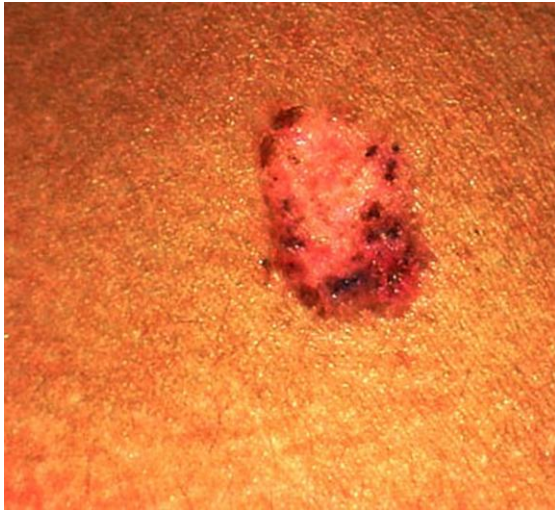


Figure 1 Annular plaque with central clearing and peripheral ridge of size 15 mm.

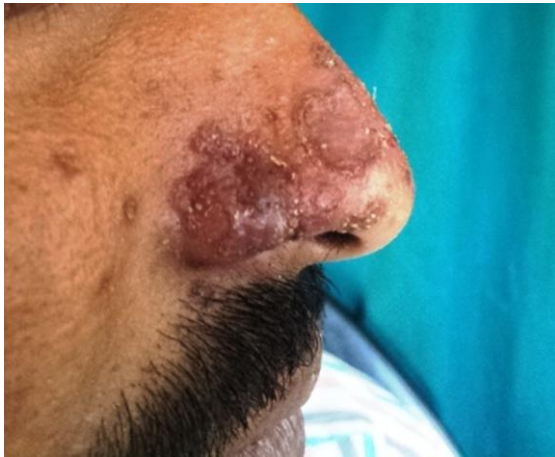

Figure 2 Annular plaques and papules with central clearing with raised peripheral edge i.e. cornoid lamella.

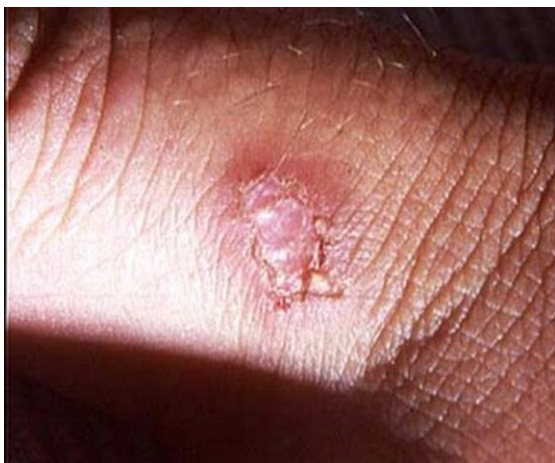

Figure 3 Single well-defined plaque with peripheral ridge and central clearing of size 5mm.

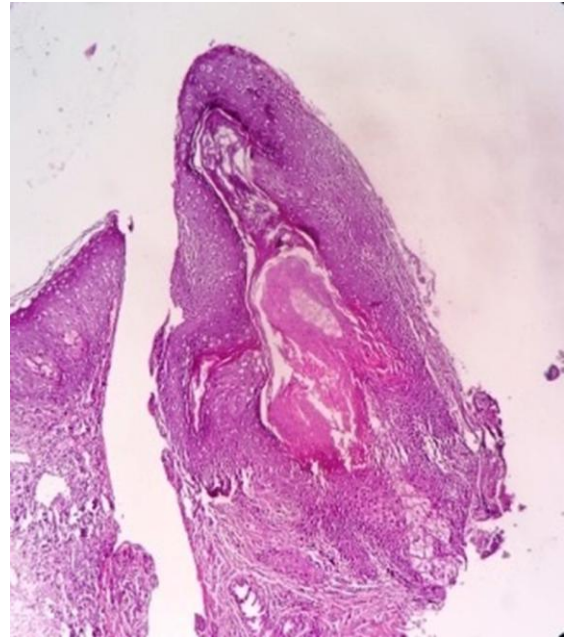


Figure 4 Epidermal invagination of keratin around glands, abnormal keratinocytes forming cornoid lamella.

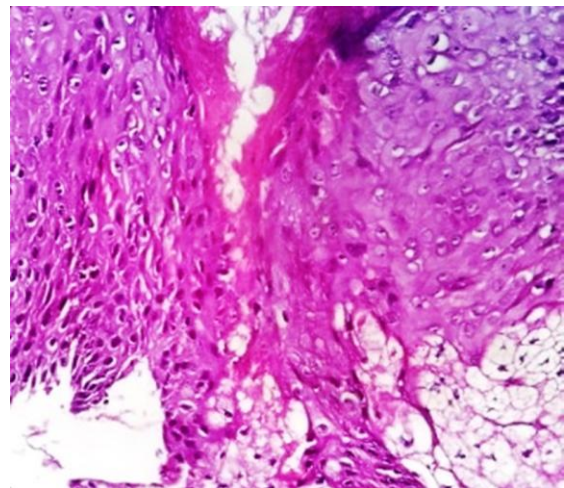


Figure 5 Abnormal keratinocyte with pyknotic nuclei few dyskeratotic cells, parakeratotic cells forming column known as cornoid lamella and dermal infiltrate with lymphocytes.

The clinical examination revealed annular plaque with central clearing and peripheral ridge of size 15 mm diameters over abdomen in case of father (**Figure 1**). In case of First son, it revealed annular papules, annular plaques with central clearing and raised peripheral edge of different sizes varying from 2mm to 20 mm over dorsum of nose and ala nasi, distributed bilateral symmetrically (**Figures 2 and 3**). In case of Second son, it revealed single well defined plaque with

peripheral ridge and central clearing of size 5mm diameter over middle finger of right hand (**Figure 4**). A full depth skin biopsy was taken from the outer part of the lesion with a 2 mm disposable skin biopsy punch and subjected to histopathology.

The histopathology revealed foci of epidermal invagination filled with keratin and parakeratosis cornoid lamella. Dermis showed a mild to moderate infiltrate of lymphocytes (**Figures 5 and 6**). On the basis of history, clinical examination and histopathology, a diagnosis of plaque type of porokeratosis of Mibelli was made. Topical tretinoin was prescribed for the management of the lesion.

Discussion

Porokeratosis is a clonal disorder of keratinisation characterized by one or more atrophic patches surrounded by a clinically and histologically distinctive hyperkeratotic ridge-like border called the cornoid lamella. Porokeratosis of Mibelli may be familial, inherited as an autosomal dominant disorder with the onset in childhood or sporadic with later onset. Clonal proliferation of atypical keratinocytes showing abnormal terminal keratinocyte differentiation leads to the formation of the cornoid lamella, that corresponds to the raised, hyperkeratotic border observed clinically.⁴ The atypical keratinocytes show abnormal differentiation but do not show an increased rate of proliferation.⁵

These include classic porokeratosis of Mibelli, Disseminated superficial actinic porokeratosis, punctate porokeratosis, porokeratosis palmaris et plantaris disseminate and linear Porokeratosis.¹ Atypical types are facial and giant porokeratosis, porokeratosis ptychotropica and porokeratoma. In addition, there are the rare forms of porokeratosis, i.e. porokeratotic adnexal ostial nevus, porokeratotic eccrine ostial and dermal duct nevus and porokeratotic eccrine and hair

follicle nevus. Other forms are punched-out, hypertrophic verrucous and reticulate porokeratosis.

Porokeratosis of Mibelli is the most characteristic and distinctive variant of the five described forms of porokeratosis. The classical form of Mibelli consists of a single plaque, or a small number of plaques, of variable size and most often affects the limbs, particularly the hands and feet, the neck and shoulders, although any part of the body may be affected including the mucous membranes, scrotum.⁶

Natural or artificial ultraviolet radiation, electron beam therapy, and extensive radiation therapy are well established trigger factors for disseminated superficial actinic Porokeratosis and porokeratosis of Mibelli. Disseminated superficial actinic porokeratosis may coexistent with linear porokeratosis and giant porokeratosis.⁷ Porokeratosis may be associated with diabetes mellitus, HIV infection, liver disease, renal transplant, and hematologic or solid organ malignancy.

Male-to-male transmission in the family reported by Bloom and Abramowitz (1943) is consistent with autosomal dominant inheritance. The male: female ratio of patients with this disorder is said to be 3 to 1 (Goertler and Jung, 1975).⁸ The existence of a non familial form has been proposed (Bhutani *et al.*, 1977).⁹

Histopathology of Porokeratosis shows hyperkeratosis with discrete parakeratotic column at margin. Diagnostic feature is cornoid lamella which represents visibly raised margin of the lesion. It is a Parakeratotic column overlying a small vertical zone of dyskeratotic and vacuolated cells within the epidermis along with focal loss of granular cell layer, mild lymphocytic infiltrate may be seen.

The approach to treatment is based on many factors, such as lesion size and location, risk of malignant transformation, and functional and

aesthetical considerations. Sun protection, emollients, and observation for signs of malignant degeneration are mandatory. It has been treated with topical 5-fluorouracil, CO2 laser vaporization, cryotherapy, topical retinoid, imiquimod, shave excision, curettage, linear excision, photodynamic therapy and dermabrasion with variable success.

Conclusion

A classical form of porokeratosis over unusual sites is easily confused with other chronic skin disorders. Usually patients never seek advice because lesions may remain asymptomatic. Histopathological examination is required for diagnosis and early identification of neoplastic changes. Here, we reported a family with porokeratosis of Mibelli. To the best of our knowledge, a very few cases reported in dermatology literature so far.¹⁰

In Indian dermatology literature to the best of our knowledge, no case report exists so far with familial inheritance between two generations.

References

1. Ruiz Villaverde R, Alonso Corral MJ, Sanchez Cano D *et al.* Linear porokeratosis of Mibelli. *An Pediatr (Barc)*. 2005;**63**:376-7.
2. Bacharach-Buhles M, Weindorf N, Altmeyer P. Porokeratosis Mibelli gigantea. *Hautarzt*. 1990;**41**:633-5.
3. Lin JH, Hsu MM, Sheu HM, Lee JY. Coexistence of three variants of porokeratosis with multiple squamous cell carcinomas arising from lesions of giant hyperkeratotic porokeratosis. *J Eur Acad Dermatol Venereol*. 2006;**20**:621-3.
4. Hartman R, Rizzo C, Patel R *et al.* Porokeratosis palmaris et plantaris disseminata or a disseminated late-onset variant of porokeratotic eccrine ostial and dermal ductal nevus (PEODDN) with follicular involvement. *Dermatol Online J*. 2009;**15** (8):8.
5. Jurecka W, Neumann RA, Knobler RM. Porokeratoses: immunohistochemical, light and electron microscopic evaluation. *J Am Acad Dermatol*. 1991;**24**:96-101.
6. Dongre A, Adhe V, Sanghavi S. Genital Porokeratosis: A rare entity. *Indian J Dermatol*. 2013;**58**:81-3.
7. Vasudevan B, Chatterjee M, Grewal R *et al.* A case of disseminated superficial porokeratosis associated with giant Porokeratosis in pregnancy. *Indian J Dermatol*. 2014;**59**:492-4.
8. Goerttler EA, Jung EG. Porokeratosis of Mibelli and skin carcinoma: a critical review. *Humangenetik*. 1975;**26**:291-6.
9. Bhutani LK, Kanwar AJ, Singh OP. Porokeratosis of Mibelli with unusual features. *Dermatologica*. 1977;**155**:296-300.
10. Commens CA, Shumack SP. Linear porokeratosis in two families with disseminated superficial actinic porokeratosis. *Pediatr Dermatol*. 1987;**4**:209-14.