

Case Report

Tinea pseudomibricata due to *Trichophyton mentagrophytes*: a rare case report

Sumir Kumar, Nidhi Kamra, Bharat Bhushan Mahajan

GGs Medical College & Hospital, Faridkot, Punjab, India

Abstract Tinea pseudoimbricata is characterized by concentric scaly rings simulating tinea imbricata but caused by dermatophytes other than *Trichophyton concentricum*. We report a unique case of tinea pseudoimbricata, its pathogenesis and review of previously reported cases. A 1.5-year-old baby developed concentric rings of scaly lesions over groins and buttocks following use of topical corticosteroids for 1 month. Mycological studies were performed to establish the diagnosis. Diagnosis of tinea pseudoimbricata was made on the basis of morphology of lesions and was confirmed by isolation of *T. mentagrophytes* on culture. Complete clinical and mycological cure was obtained with topical 1% sertaconazole given for 4 weeks.

Key words

Tinea imbricata, tinea pseudoimbricata, *Trichophyton mentagrophytes*.

Introduction

Tinea imbricata is an anthropophilic dermatophytosis caused exclusively by *Trichophyton concentricum* that is primarily seen in individuals of pure race residing in primitive isolated conditions and often is associated with poor hygiene.¹ The exact mode of inheritance is unknown. It may have autosomal inheritance with incomplete penetrance/ autosomal recessive inheritance. Apart from genetic predisposition other factors implicated in causation include poor hygiene, impaired delayed type hypersensitivity reaction to *T. concentricum* antigen and T-lymphocyte hyporeactivity that leads to repeated waves of scaling in tinea imbricata.²

Tinea pseudoimbricata is an unusual form of tinea corporis/ tinea cruris masquerading as tinea imbricata irrespective of the etiological agent.

Case report

A 1.5-year-old baby was brought with annular erythematous plaques over the groins and buttocks since 3 months. Family history was negative for dermatophytosis. No evidence of protein energy malnutrition was present. History of application of topical corticosteroids was present since 1 month. On examination multiple, erythematous, concentric and circumscribed scaly patches were seen over the groins and gluteal folds (**Figure 1**). Differential diagnosis included tinea cruris and erythema annulare centrifugum. Provisional diagnosis of tinea imbricata was made on the basis of typical morphology of lesions. KOH mount of the scrapings taken from the margins of all the concentric rings revealed hyaline, septate, branching hyphae with several anthroconidia (**Figure 2**). Culture on Sabouraud's dextrose agar demonstrated creamish white colony with granular surface and raised centre; reverse showed yellowish brown pigmentation consistent with *Trichophyton mentagrophytes* (**Figure 2**). Trichophyton test could not be done. Patient was treated with 1% sertaconazole cream for 4 weeks with complete resolution of lesions.

Address for correspondence

Dr. Dr. Nidhi Kamra

GGs Medical College & Hospital

Faridkot, Punjab, India

Email: Nidhikamra06@gmail.com

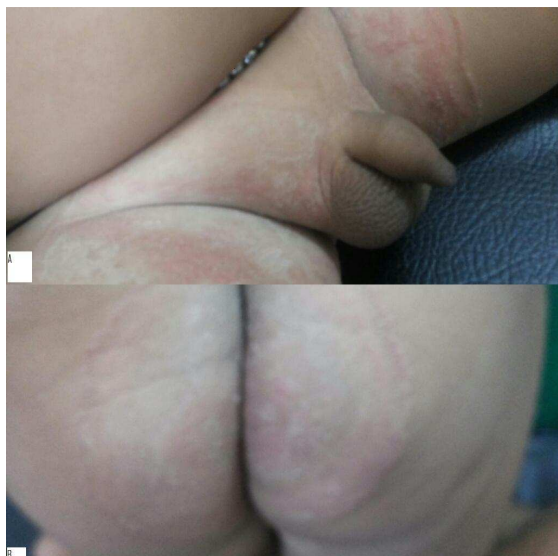

Figure 1 Multiple, erythematous, concentric and circumscribed scaly patches were present over the groins and gluteal folds.

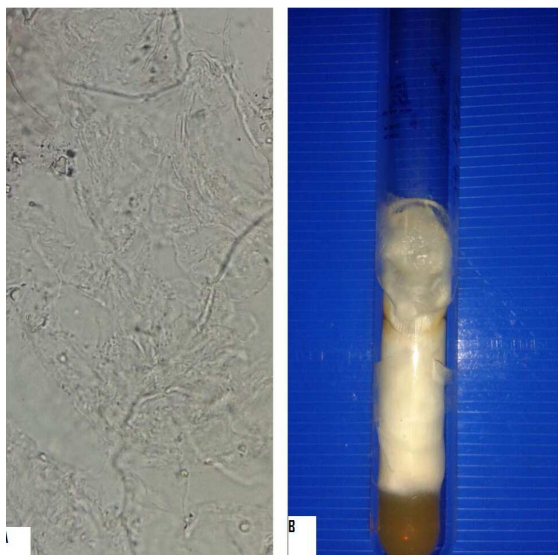


Figure 2 Hyaline, septate, branching hyphae with several anthroconidia on microscopy. Culture on Sabouraud's dextrose agar showed creamish white colony with granular surface and raised centre.

Discussion

The term 'imbricata' is derived from the latin 'imbrex' and refers to the similarity to overlapping roof tiles. The unusual clinical picture seen in our patient is reminiscent of the rash described in tinea imbricata due to *Trichophyton concentricum*

Normally in response to dermatophytoses, the stratum corneum undergoes renewal process

done by keratinocytes that leads to epithelial shedding, and consequently possible removal of the fungus.³ Also cell-mediated immune response is responsible for the control of infection.

In tinea pseudoimbricata impaired cell-mediated immune response due to application of topical corticosteroids would have resulted in persistence of fungi and formation of concentric rings. Also adhesion of *T. mentagrophytes* anthroconidia to the stratum corneum surface results in the formation of elongated fibrillary structures that appear to anchor and connect the anthroconidia to the tissue surface. This may prevent its removal from the host tissue.⁴

First reported case of tinea pseudoimbricata dates back to 1987, where *Microsporum ferrugineum* was the culprit fungi.⁵ Pei-Lun Sun described similar presentation with *M. gypseum*. None of them described associated immunodeficiency.⁶

Narang *et al.*⁷ reported a case of tinea capitis with concentric rings in an HIV-reactive patient due to *T. tonsurans*. Concentric rings were present over the entire scalp and forehead with diffuse thinning of hairs. Patient's CD 4 count was 99 cells/mm³. Complete clinical and microbiological cure was observed with oral terbinafine given for 3 weeks.

Lim and Smith⁸ described extensive tinea corporis resembling tinea imbricata in a renal transplant recipient on immunosuppressive therapy. In this case, too, *T. tonsurans* was the culprit agent. Patient was maintained on tacrolimus and azathioprine. The similarity in clinical presentation was attributed to immunosuppressive processes utilized in preventing renal transplant rejection and that seen in immune response of patients with tinea imbricata.⁸

Batta *et al.*⁹ reported two patients of tinea corporis due to *T. tonsurans* and *T.*

mentagrophytes. Cause of immunosuppression was due to use of cyclical therapy with topical corticosteroids and topical antifungals because of indecision about the etiology of rash and its treatment.

A case report by Horque and Horden¹⁰ described concentric rings in a 44 years old Afro-Caribbean woman. Her annular erythema was diagnosed as that of lupus erythematosus and was treated with oral and topical corticosteroids and hydroxychloroquine but the rash continued to worsen. On repeating skin scrapings for culture *T. tonsurans* growth was obtained and rash cleared completely with oral terbinafine for 4 weeks.

A recent case report by Rao and Datta¹¹ described similar presentation due to *T. mentagrophytes* and *T. tonsurans*. Cause of immunosuppression in one of the cases was protein-energy malnutrition.

Thus on reviewing the literature it can be concluded that irrespective of immunological status, etiological agent and age, tinea corporis/ tinea cruris can morphologically resemble tinea imbricata.

Though immunosuppression has been postulated as a cause, more research about different aspects of dermatophytoses such as physiology, genetics, biochemistry and immunology is required to elucidate the cause in immunocompetent individuals.

References

1. Bonifaz A, Archer-Dubon C, Saúl A. Tinea imbricata or Tokelau. *Int J Dermatol*. 2004;**43**:506-10.
2. Hay RJ, Reid S, Talwat E *et al*. Immune responses of patients with tinea imbricata. *Br J Dermatol*. 1983;**108**:581-6.
3. Wagner DK, Sohnle PG. Cutaneous defenses against dermatophytes and yeasts. *Clin Microbiol Rev*. 1995;**8**:317-35.
4. Kaufman G, Horwitz BA, Duek L, Ullman Y, Berdicevsky I. Infection stages of the dermatophyte pathogen *Trichophyton*: microscopic characterization and proteolytic enzymes. *Med Mycol*. 2007;**45**:149-55.
5. Lee KH, Lee ES, Kang WH, Lee S. An unusual clinical manifestation of tinea corporis caused by *Microsporon ferrugineum*. *Korean J Dermatol*. 1987;**25**:383-8.
6. Sun PL, Ho HT. Concentric rings: An unusual presentation of tinea corporis caused by *Microsporum gypseum*. *Mycoses*. 2006;**49**:150-1.
7. Narang K, Pahwa M, Ramesh V. Tinea capitis in the form of concentric rings in an HIV positive adult on antiretroviral treatment. *Indian J Dermatol*. 2012;**57**:288-90.
8. Lim SP, Smith AG. Tinea pseudoimbricata: Tinea corporis in a renal transplant recipient mimicking the concentric rings of tinea imbricata. *Clin Exp Dermatol*. 2003;**28**:331-4.
9. Batta K, Ramlogan D, Smith AG *et al*. Tinea indecisiva may mimic the concentric rings of tinea imbricata. *Br J Dermatol*. 2002;**147**:384.
10. Horque SR, Holden CA. *Trichophyton tonsurans* infection mimicking tinea imbricata. *Clin Exp Dermatol*. 2007;**32**:345-6.
11. Rao AG, Datta N. Tinea corporis due to *Trichophyton mentagrophytes* and *Trichophyton tonsurans* mimicking tinea imbricata. *Indian J Dermatol Venereol Leprol*. 2013;**79**:554.